

## Robot-Assisted Adrenalectomy for a Giant Adrenal Myelolipoma: One of the Largest Tumors Removed by a Minimally Invasive Approach

Avishek Mandal<sup>1</sup>, Shikhar Chohan<sup>2</sup>, Neha K Madan<sup>2</sup>, Puneeth Medapati<sup>1</sup>, Rohan Nautiyal<sup>1</sup>, Niraj Kumar<sup>1</sup>, Pawan Vasudeva<sup>1</sup>

Cite this article: Mandal A, Chohan S, Madan NK, Medapati P, Nautiyal R, Kumar N, Vasudeva P: Robot-Assisted Adrenalectomy for a Giant Adrenal Myelolipoma: One of the Largest Tumors Removed by a Minimally Invasive Approach. *Ann Urol Oncol* 2026, 9: 3. <https://doi.org/10.32948/auo.2026.03.28>

### Abstract

**Background** Adrenal myelolipomas are rare, benign tumors composed of adipose and hematopoietic tissue. While often asymptomatic, tumors larger than 10 cm—termed "giant"—may require surgical removal owing to the mass effect. The robotic approach to adrenalectomy offers a minimally invasive alternative to open surgery. This case is reported for its novelty, being one of the largest adrenal myelolipoma removed robotically to date.

**Case presentation** A 36-year-old woman of South Asian ethnicity presented with mild, recurrent right flank pain for 8 months. Imaging revealed a right adrenal mass (10.5 × 10.8 × 12.2 cm), which was consistent with myelolipoma. She underwent robot-assisted laparoscopic adrenalectomy using the Da Vinci Xi platform. The tumor, which closely abutted the hepatic vein, was successfully removed without complications. Final pathology confirmed a myelolipoma measuring 18.2 × 13.5 × 5.5 cm and weighing 1030 grams—one of the largest such tumors reported to have been removed robotically.

**Conclusions** This case highlights the feasibility and safety of robotic adrenalectomy for giant adrenal tumors in experienced hands. It sets a precedent for managing such large tumors minimally invasively and expands the scope of robotic surgery in adrenal pathology.

**Key words** Adrenal myelolipoma, robotic adrenalectomy, giant adrenal tumor, minimally invasive surgery, case report

1. Department of Urology and Renal Transplant, Vardhaman Mahavir Medical College and Safdarjung Hospital, New Delhi, India.

2. Department of Pathology, Vardhaman Mahavir Medical College and Safdarjung Hospital, New Delhi, India.

Correspondence: Shikhar Chohan (Department of Pathology, Vardhaman Mahavir Medical College and Safdarjung Hospital, New Delhi, India; Email: [shikhar.chohan1993@gmail.com](mailto:shikhar.chohan1993@gmail.com)).

## Introduction

Adrenal myelolipomas are nonfunctional benign tumors composed of adipose and hematopoietic tissue [1]. While usually asymptomatic, those exceeding 10 cm—termed "giant"—may present with abdominal pain or mass effects on adjacent structures. Surgical excision is recommended for symptomatic patients. Traditionally, large adrenal tumors are managed via open adrenalectomy. In recent years, robotic-assisted adrenalectomy has emerged as a safe and feasible alternative, even for tumors previously considered too large for minimally invasive techniques. Here, we present the case of a 36-year-old South Asian female with a large adrenal tumor. To the best of our knowledge, this is one of the largest reported tumors successfully removed using a minimally invasive approach.

## Case presentation

A 36-year-old previously healthy South Asian woman presented with mild, recurrent right flank pain persisting for the past 8 months. Abdominal ultrasound revealed a right adrenal mass, and subsequent contrast-enhanced CT imaging demonstrated a well-defined lesion measuring 10.5 × 10.8 × 12.2 cm with predominant fat attenuation (−80 to −100 HU) and focal areas of higher attenuation (up to 112 HU), likely representing hematopoietic elements, consistent with adrenal myelolipoma (**Figure 1A, 1B**). Preoperative hormonal evaluation including serum cortisol, plasma metanephrines, and aldosterone-renin ratio was performed and found to be within normal limits, confirming a non-functional lesion.

The patient was positioned in a left lateral decubitus position. A standard four-port robotic configuration was used with the Da Vinci Xi system (**Figure 2**). Robot-assisted laparoscopic right adrenalectomy was performed. Following mobilization of the liver by dividing the right triangular and falciform ligaments, careful dissection was carried out to identify and control the adrenal vein and its tributaries draining into the inferior vena cava (IVC). The

tumor was well encapsulated and closely abutted the hepatic vein, requiring meticulous dissection to avoid vascular injury (**Figure 3A–D**). The mass was mobilized from surrounding structures without capsular disruption and retrieved using an endoscopic retrieval bag to prevent spillage. The estimated blood loss was 200 mL, total operative time was 230 minutes, and robotic console time was 174 minutes.

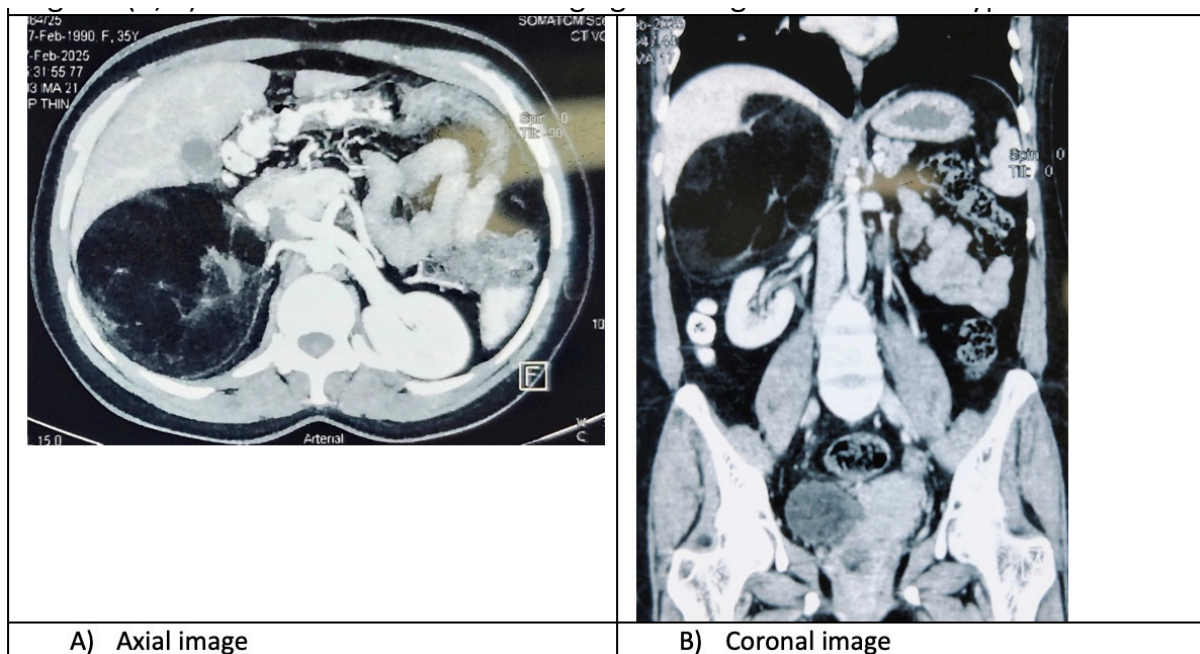
The patient had an uneventful postoperative recovery and was discharged on day 3.

Gross pathology revealed a tumor measuring 18.2 × 13.5 × 5.5 cm and weighing 1030 grams. Histopathological examination confirmed the diagnosis of adrenal myelolipoma, which was composed of mature adipose tissue with interspersed hematopoietic elements and no signs of malignancy (**Figure 4A–C**).

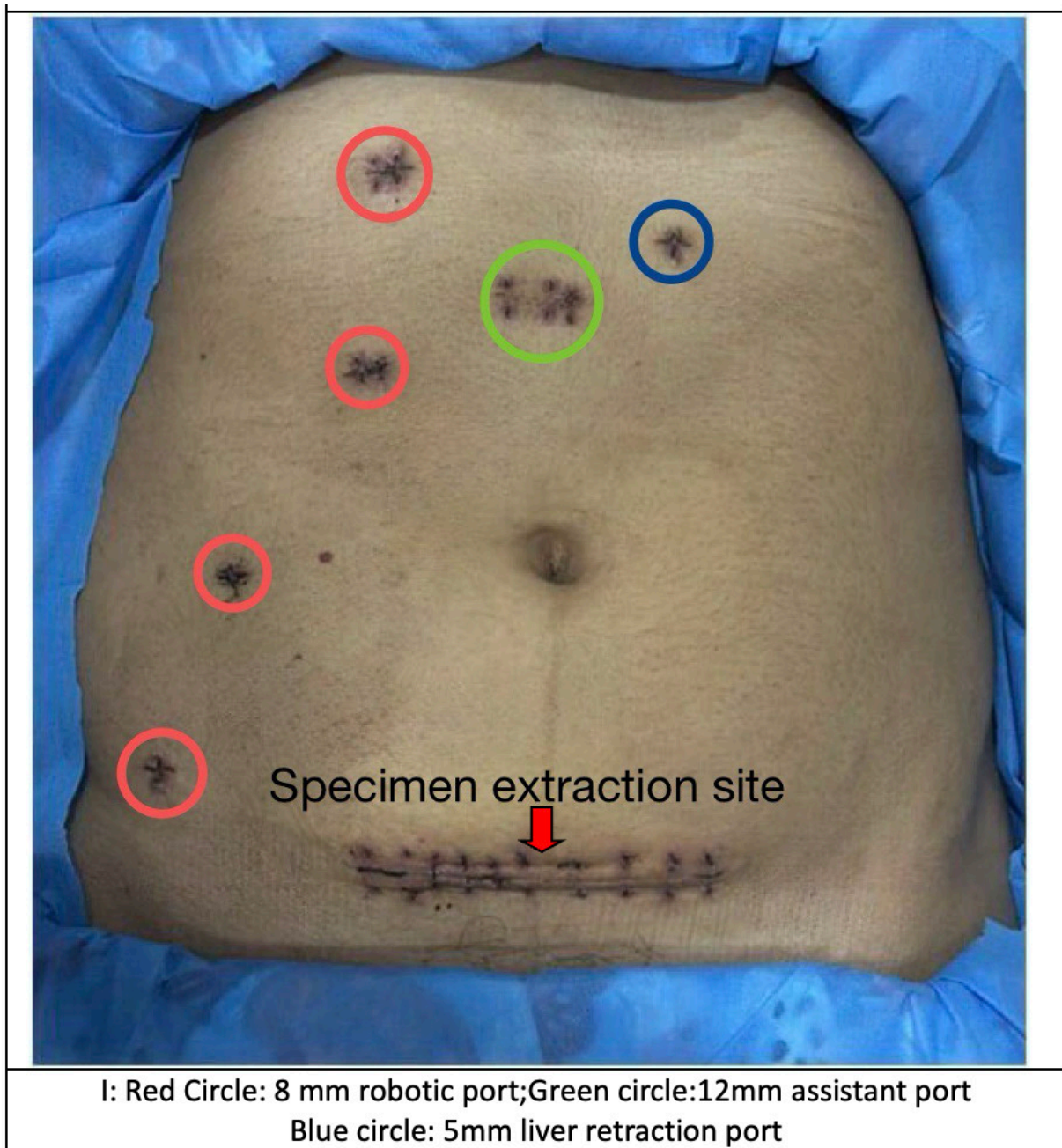
## Discussion and conclusions

Giant adrenal myelolipomas, although benign, may become symptomatic due to mass effect and often require surgical intervention. Traditionally, large adrenal tumors were managed with open adrenalectomy because of concerns regarding malignancy, local invasion, and the risk of intraoperative capsular disruption.

With increasing experience, minimally invasive approaches, including laparoscopic and robotic adrenalectomy, have been successfully applied to larger adrenal tumors. While an upper size limit of approximately 10–12 cm has been suggested for laparoscopic adrenalectomy, this threshold remains less clearly defined for robotic surgery [2, 3]. Tumor size can pose technical challenges by limiting visualization and instrument maneuverability, thereby increasing the risk of capsular rupture and incomplete resection. However, evidence suggests that size alone should not be considered an absolute contraindication, and the absence of local invasion on preoperative imaging remains the most important factor in selecting a minimally invasive approach [4].



**Figure 1.** Contrast-enhanced CT showing a well-defined hypodense adrenal mass. (A) Axial view; (B) Coronal view.



**Figure 2.** Port placement and specimen extraction site following robot-assisted right adrenalectomy. (A) Red circles indicate 8 mm robotic ports; (B) Green circle indicates the 12 mm assistant port; (C) Blue circle indicates the 5 mm liver retraction port. The lower transverse incision (arrow) marks the specimen extraction site.

Robotic adrenalectomy offers several advantages over conventional laparoscopy, including enhanced dexterity, three-dimensional visualization, and improved instrument stability. The use of the fourth robotic arm provides consistent retraction and improved exposure, facilitating meticulous dissection around critical vascular structures. Previous studies have reported that for adrenal tumors larger than 5–6 cm, robotic adrenalectomy may be associated with shorter operative time, reduced blood loss, and lower conversion rates compared with laparoscopy [5, 6].

Surgeon experience plays a crucial role in determining the feasibility of a robotic approach for large adrenal tumors. With adequate expertise, en bloc tumor resection can be achieved safely while preserving surrounding structures. Recent reports

have demonstrated successful robotic adrenalectomy for tumors measuring up to 15–17 cm [7, 8]. This case adds to the growing body of evidence supporting the feasibility of robotic surgery in large adrenal tumors.

In our case, preoperative CT imaging reliably suggested myelolipoma based on the presence of macroscopic fat, and no local invasion was identified, allowing for a minimally invasive approach. However, imaging may underestimate tumor size, as previously reported, which was also observed in our case [9].

The final resected specimen measured 18.2 × 13.5 × 5.5 cm and represents one of the largest adrenal tumors removed robotically in the literature.

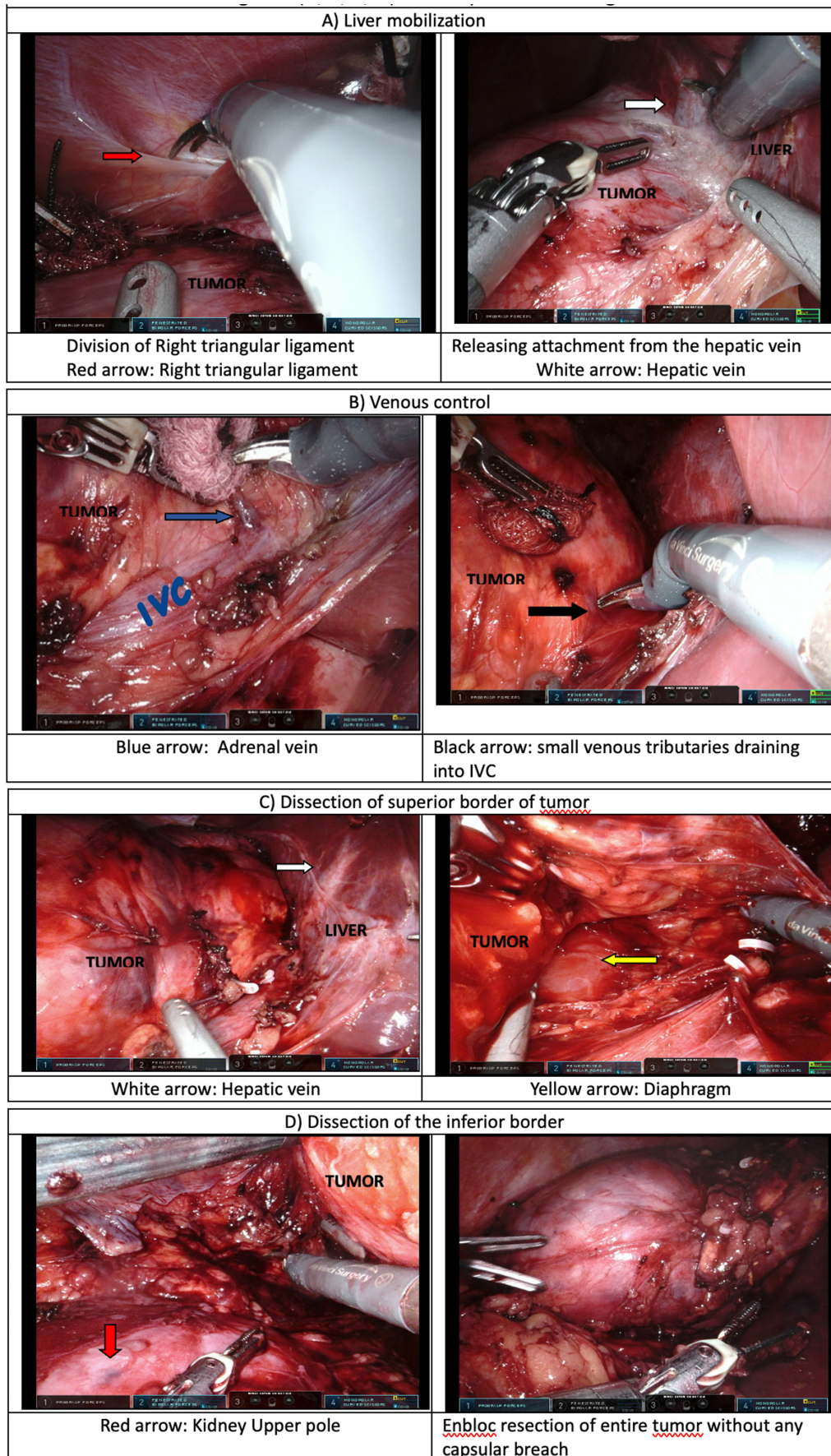
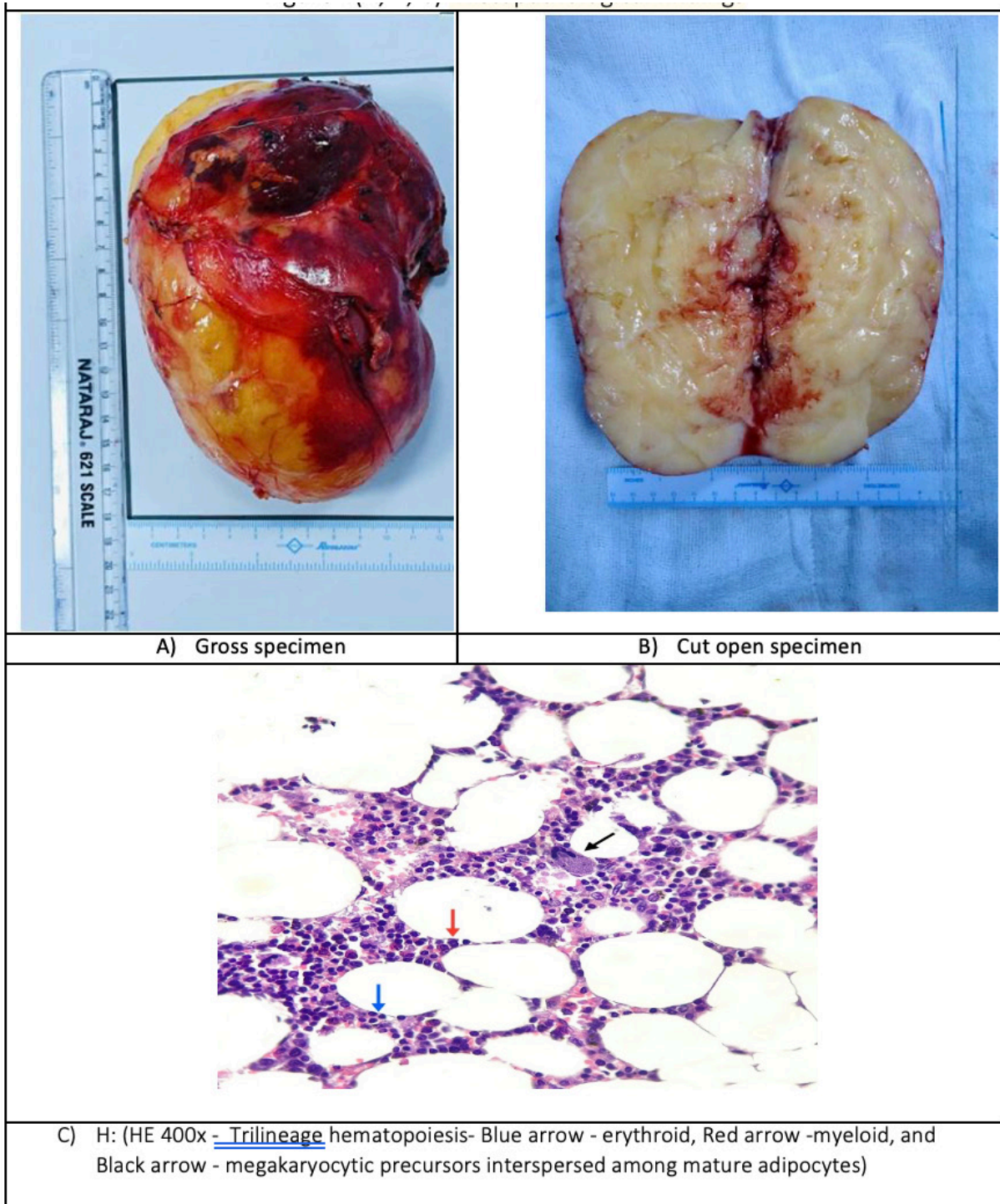


Figure 3. Intraoperative steps of robot-assisted adrenalectomy. (A) Liver mobilization; (B) Venous control; (C) Dissection of the superior border of the tumor; (D) Dissection of the inferior border of the tumor.



**Figure 4.** Histopathological features of adrenal myelolipoma. (A) Gross specimen; (B) Cut surface of the tumor; (C) Hematoxylin and eosin stain (×400) showing trilineage hematopoiesis (blue arrow: erythroid, red arrow: myeloid, black arrow: megakaryocytic precursors) admixed with mature adipocytes.

**Conclusion**

Robotic adrenalectomy is a safe and effective approach for selected large adrenal tumors. Careful patient selection, absence of local invasion, and surgical expertise are key factors in achieving optimal outcomes.

**Ethics approval and consent to participate**

Not applicable.

**Consent for publication**

Written informed consent was obtained from the patient for publication of this case report and any accompanying images. A copy of the written consent is available for review by the Editor-in-

Chief of this journal.

#### Availability of data and materials

Not applicable.

#### Conflict of interests

The authors declare that they have no competing interests.

#### Funding

No funding was received.

#### Authors' contributions

AM: Conceptualization, Data curation, Writing – original draft.

PM: Conceptualization, Data curation.

SC: Histopathological analysis, microscopy imaging, writing – review and editing, corresponding author.

NKM: Histopathological analysis, Writing – review & editing.

RN: Writing – review & editing.

NK: Surgical supervision, Writing – review & editing.

PV: Surgical procedure, Resources, Final approval of manuscript.

#### Acknowledgments

Not applicable.

#### Reference

1. Bokhari MR, Zulfiqar H, Garla VV: Adrenal Myelolipoma. In: StatPearls. Treasure Island (FL): StatPearls Publishing; 2023.
2. Henry JF, Sebag F, Iacobone M: Results of laparoscopic adrenalectomy for large and potentially malignant tumors. *World J Surg* 2002, 26(8): 1043-1047.
3. MacGillivray DC, Whalen GF, Malchoff CD, Oppenheim DS, Shichman SJ: Laparoscopic resection of large adrenal tumors. *Ann Surg Oncol* 2002, 9(5): 480-485.
4. Varghese B, Moinuddin Z, Augustine T: Laparoscopic approaches to adrenalectomy for large adrenal tumours: A systematic review. *Laparosc Surg* 2022, 6: 38.
5. Agcaoglu O, Aliyev S, Karabulut K, Mitchell J, Siperstein A, Berber E: Robotic versus laparoscopic resection of large adrenal tumors. *Ann Surg Oncol* 2012, 19(7): 2288-2294.
6. Morelli L, Tartaglia D, Bronzoni J, Palmeri M, Guadagni S, Di Franco G, Gennai A, Bianchini M, Bastiani L, Moglia A, et al: Robotic assisted versus pure laparoscopic surgery of the adrenal glands: A case-control study comparing surgical techniques. *Langenbecks Arch Surg* 2016, 401(7): 999-1006.
7. Shah P, Ragavan N, Bhat S, Dholakiya K: Case report: Robot-assisted laparoscopic excision of giant ganglioneuroma of the adrenal gland. *J Robot Surg* 2018, 12(3): 553-555.
8. Cochetti G, Paladini A, Boni A, Silvi E, Tiezzi A, De Vermandois JAR, Mearini E: Robotic treatment of giant adrenal myelolipoma: A case report and review of the literature. *Mol Clin Oncol* 2019, 10(5): 492-496.
9. Lau H, Lo CY, Lam KY: Surgical implications of underestimation of adrenal tumor size by computed tomography. *Br J Surg* 1999, 86(3): 385-387.