



Diagnosis and Treatment of Adrenal Metastasis in Modern Era

Sarah E. Matusofsky^{1,*}, Paris M. Fang^{1,*}, Ellie R. Monnette¹, Austin M. Kim², Mark R. Wakefield^{1,3}

Cite this article: Matusofsky ES, Fang MP, Monnette RE, Kim MA, Wakefield RM: Diagnosis and Treatment of Adrenal Metastasis in Modern Era. *Ann Urol Oncol* 2023, 6(4): 127-131. <https://doi.org/10.32948/auo.2023.11.07>

Abstract

The adrenal glands are a common site of metastases in many advanced stages of cancers such as lung cancer and breast cancer. Given the frequent asymptomatic nature of these adrenal metastatic tumors, patients seldom get screened for adrenal metastases unless otherwise medically indicated for. Therefore, it is essential that screening methods should be as accurate and precise as possible. In this review, we summarize the pivotal role of modern screening in the early detection of adrenal metastatic lesions and detail the advancements that have contributed to improved detection. Through our review, we reaffirm that there has yet to be a “gold standard” in the screening process for adrenal metastases. Such a study can help medical professionals more comprehensively understand the contemporary screening methods, promoting early detection and better prognosis of adrenal metastases.

Key words adrenal metastatic tumors, biopsy, imaging

1. Department of Surgery, University of Missouri School of Medicine, Columbia, MO, USA.

2. Department of Microbiology, Immunology & Pathology, Des Moines University, Des Moines, IA, USA.

3. Ellis Fischel Cancer Center, University of Missouri School of Medicine, Columbia, MO, USA.

* These authors contribute equally.

Correspondence: Mark R. Wakefield (Department of Surgery, University of Missouri School of Medicine, Columbia, MO, 65212, USA; Email: wakefieldmr@health.missouri.edu).

Introduction

The adrenal glands are endocrine organs responsible for the production of steroid hormones. These hormones are vital in the body's fight-or-flight response and the production of catecholamines that mediate various central nervous system processes such as motor and cognition. Masses in adrenal glands can disrupt the regular secretions of these steroid hormones and can be classified as either functional or non-functional depending on whether the secretions of the mass are excessive and cause clinical symptoms. Both functional and non-functional masses can further be classified as either benign or malignant. Malignant tumors are featured by invasion of surrounding tissues and metastasize to locations away from the original location. Malignant adrenal tumors are significant in that the adrenal gland is the 4th most common site of metastasis in cancers [1]. In fact, adrenal metastases are the 2nd most common type of tumor found in the adrenal gland after benign adenomas [1]. This is significant given the relatively small size of the adrenals; the right and left adrenal glands have an average maximum width of 0.61 cm and 0.79 cm, respectively [2]. Additionally, adrenal metastases have the most common recurrence of all adrenal gland malignancies [1]. Clinically, these malignant growths are almost always linked to an initial cancer diagnosis but are typically underdiagnosed because most patients with adrenal metastases are asymptomatic. Among patients who do show symptoms, clinical presentations include localized back and/or abdominal pain and seldom seen adrenal insufficiency. As a result of the lack of symptoms, adrenal metastases lack screening and tend to only be discovered after death with autopsy or incidentally with routine screenings [1, 2]. This issue of underdiagnosis is further compounded by the fact that radiographic scans have historically yielded low accuracy [1]. However, recent advances in screening technology such as radiological scans, biopsy, and biochemical evaluation (**Figure 1**) have led to higher accuracy in the identification of adrenal lesions.

Diagnosis of adrenal metastasis

Adrenal glands are a common site of metastases for many primary cancers. In fact, there are very few instances where adrenal metastases appear without the discovery of a detectable primary tumor [3-4]. For instance, 39% of adrenal metastases occur from a primary cancer in the lungs, and 53% of patients with primary lung cancer develop adrenal metastases [5]. Other common cancers that often metastasize to the adrenal glands are breast cancer, pancreatic cancer, renal cancer, esophageal cancer, liver cancer, melanoma and gastrointestinal tract cancers [4, 6-10]. During autopsies of patients with a medical history of renal cell carcinoma, the most common type of renal cancer, the percentage of adrenal metastases discovery was between 6% to 29%. Overall, 27% of malignant tumors were found to have caused adrenal metastasis in autopsy studies [11]. Adrenal metastases take an average of 2.5 years to identify after the diagnosis of a primary cancer. It is recommended for patients diagnosed with cancers that often metastasize to the adrenal glands to get abdominal imaging to screen for presence of adrenal lesions. With the increased role of imaging, this identification period for adrenal metastasis may be shrinking [12]. It is not surprising that it may be difficult to identify a patient with adrenal metastases because lesions are typically asymptomatic. In instances where patients do present with symptoms, generic symptoms may include back and abdominal pain as a result of the large mass growth. This difficulty to diagnose based on symptoms is reflected in a retrospective cohort study of 579 patients with adrenal metastases where only 5% of patients were diagnosed with adrenal metastases based on symptoms. The majority were discovered during cancer staging

(58.5%) or discovered incidentally (36.3%) [13]. Therefore, precise identification of adrenal abnormalities holds significant importance, particularly among cancer patients, as the detection of adrenal metastases significantly impacts both prognosis and the choice of treatment [12]. For patients with cancers that less commonly metastasize to the adrenal glands—such as uterine cancer, thyroid cancer, and bladder cancer—it may be less necessary to undergo a preventative screening if no symptoms have surfaced [14-16]. Identification of adrenal metastasis in patients who have not been diagnosed with cancer prompts physicians to search for a very likely underlying cancer [15].

Imaging

The management of the primary malignancy is influenced by the presence of metastases. Although most adrenal tumors belong to the category of benign, many of these tumors are indeterminate on imaging with current technology. Computed tomography (CT), ultrasound scan (US), and the combination of CT and US are the most commonly used types of scans used for adrenal biopsies [18]. Based on current studies, there is not a single scan with 100% dependability that can comprehensively evaluate adrenal incidentalomas or a scan with close to 100% dependability for distinguishing malignant from benign adrenal masses. In addition, many of these scans have limitations. For example, ultrasounds can be limited in larger patients [18]. CT and magnetic resonance imaging (MRI) scans are often used to identify benign lesions and are not used for adrenal malignancy. These scans depict lipid content, which shows whether an adrenal mass is benign (high lipid content) or potentially malignant (low lipid content). However, with CT, 30% of adrenal lesions have been incorrectly classified [19]. Fluorodeoxyglucose- positron emission tomography, or FDG-PET, and CT scans are mainly only used to detect the presence of malignant diseases. Previous imaging can be used for comparison, which can help determine the timeline of the metastasis and change over time. Further evaluation is recommended for patients with cancer that appears to have metastasized to only the adrenal glands and no other sites in the body. The choice of screening modality depends on many factors, including metastasis progression, prognosis, resources available and physician preference.

(1) CT: The adrenal mass CT protocol includes a pre-contrast scan, a portal venous phase scan, and a delay scan [20]. On CT, adrenal metastases are typically heterogeneous and have an unenhanced density greater than 10 HU. Only assessing precontrast density by itself is not specific enough because one-third of benign adrenal masses have an HU greater than 10 and have low lipid content, which are the main indicators of potentially malignant masses. In these cases, a CT scan with contrast enhancement for washout characteristics is necessary. An adrenal lesion with a precontrast HU of less than 10 is unlikely to be malignant, but in patients with extra-adrenal malignancy, there is a pooled false negative rate of 7%. In these cases, special attention should be paid to adrenal masses with even precontrast HUs of less than 10. In order to achieve better accuracy, the measurement of HU should be standardized. In measurement, two-thirds of the largest axial diameter of the region of interest should be included. Boundaries should be avoided whenever possible. If areas of necrosis are present, the measurement is inaccurate. Because large adrenal masses often include areas of necrosis, calcification, and hemorrhage, neither CT scans or MRIs are able to define their nature [19]. Adrenal masses that are greater than four centimeters are more likely to be malignant. Rapidly growing adrenal lesions, local invasion, irregular borders, and central necrosis are all good indicators of the presence of primary adrenal malignancy and adrenal metastasis. Although often found in large adrenal masses, calcification is seldom seen in metastases of the adrenal glands.

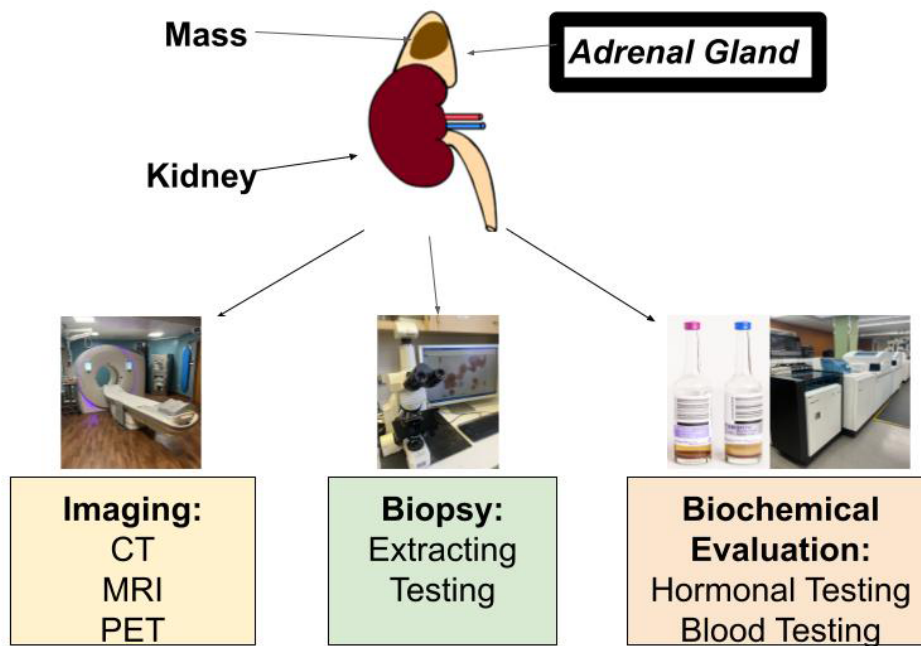


Figure 1. Methods for Evaluation of Adrenal Metastasis. Imaging techniques (left), biopsy (middle) and biochemical evaluation (right) are important methods used for detection of adrenal metastasis.

(2) MRI: MRI plays a very small role in characterizing lipid-poor masses. It plays an even smaller role in identifying adrenal masses based on pre-contrast HU values, especially values greater than 20-30 HU, which is very evident in adrenal metastases. The specific MRI that is used regularly is the chemical shift imaging technique [21]. This phenomenon conveys the differential precession frequencies of protons in lipids in water using the same imaging voxel. Many of the adrenal gland carcinomas are visual with high signal intensity on in-phase imaging and low signal intensity on out-of-phase imaging, allowing a simple visual test to be completed by the chemical shift technique. The most efficient and effective way to analyze a lesion in the adrenal gland is using the splenic intensity offered from the CSI technique [22]. However, MRI requires a lot of equipment and needles that are MRI compatible, which are typically costly [18].

(3) PET: An 18F-fluorodeoxyglucose PET (18F-FDG PET) cannot precisely mark cancer cells. However, PET is very useful when determining whether an adrenal mass is benign or malignant and the primary cancer is known because PET has high sensitivity (74-100%) and high specificity (66-100%). PET-CT cannot adequately distinguish adrenal metastases from adrenocortical carcinoma and is subject to both false-positive and false-negative results. PET-MRI offers a higher accuracy compared to PET-CT in diagnoses of other metastases, including liver metastases [23].

Biochemical evaluation

Differentiating pheochromocytoma from metastases cannot be confidently done with CT, MRI, or PET scans, so it is crucial to rule out pheochromocytoma in patients with extra-adrenal malignancy with an indeterminate mass. Plasma fractionated metanephrines elevated over 4x the normal amount or elevated 24-h urinary fractionated metanephrines are important in diagnosing pheochromocytoma [24]. Patients with Cushing syndrome and primary hyperaldosteronism-or other hyperfunctioning-would benefit from additional individualized

hormone work up. Hormonal workup is unlikely to have much benefit for patients with poor prognosis. It is recommended for all patients with suspected adrenal metastases on both glands to be clinically evaluated for adrenal insufficiency as, in some cases, it has been linked to adrenal insufficiency. Adrenal insufficiency is not typical when only one adrenal gland is affected, so evaluation for insufficiency is usually not needed. There is a chance of glucocorticoid-related adrenal suppression occurring in patients who have a history of cancer and take glucocorticoids. Procedures should be taken to prevent adrenal crisis.

Biopsy

Patients with a high likelihood of having a malignant mass are often referred for biopsy when imaging techniques (CT, MRI, PET) are insufficient in determining whether an adrenal mass is benign or malignant [25]. It is important to note that needle biopsy may not yield satisfactory results in every patient [26]. FNA, an abbreviation for CT-guided fine-needle aspiration, is practical when trying to confirm the presence of metastatic disease in adrenal lesions as it has a positive predictive value of 100%. FNA is especially useful if the management of the cancer patient would be altered with information from histology. In images with masses that have not been conclusively identified as benign and adrenal masses that are hormonally inactive, FNA is a useful method for determination. However, FNA can also yield non-diagnostic results (0-28% of the time). Complications arise 2.5%-13% of the time and can include adrenal hemorrhage, pain, pancreatitis, and hematuria. Because of the possible risk of hypertensive crisis and other life-threatening complications that could arise in the patient, it is crucial that pheochromocytoma is not included in any biochemical testing that is conducted before the biopsy. FNA should be ruled out if the adrenal lesion is likely to be adrenocortical carcinoma because of the high risk of dissemination which makes it R0 resection impractical. R0 resection refers to a surgical procedure aimed at achieving complete removal of the tumor along with clear

margins.

Treatment

The first step in most effectively treating adrenal metastases is to treat the primary cancer. Many treatment options for adrenal tumors are, in the long-term, ineffective even if the adrenal metastasis has been resected if the primary cancer has not or could not be completely resected. Chemotherapy and/or radiation therapy is often used to treat primary cancer. Surgical resection of the primary cancer can be considered in patients with adrenal metastases that have a high likelihood of being cured. Aside from treating the primary cancer, adrenalectomy can be considered if there is no local invasion and the cancer has not resurfaced for at least six months after treatment. Results of adrenalectomy will vary depending on the cancer site of origin, and there is no evidence for results of adrenalectomy in patients with an unknown primary cancer. Minimally invasive laparoscopic adrenalectomy is as effective as open adrenalectomy for adrenal mastectomy with proven reduction in postoperative pain, morbidity, and length of stay. Adrenal masses less than 6 cm without local invasion are amenable to laparoscopic adrenalectomy. However, with adrenalectomy, there are risks of tumor breakup and dissemination. Because of these risks, adrenalectomy is not consistently used, and patient situations must be assessed [5]. Following ablation, an assessment to determine adrenal function should be performed in order to ensure the safety of the patient. Glucocorticoid replacement can be provided if the patient needs it. In lung cancer patients with solitary adrenal masses, surgical resection improves prognosis for the primary cancer. It is recommended that the primary cancer be resected or able to be cured by chemotherapy before further consideration of laparoscopic adrenalectomy because of the likelihood of tumor regrowth if the primary cancer is not resected [5]. Uniquely, the standard approach in treating adrenal malignancies with origins from renal cancers is selective inclusion of ipsilateral adrenalectomy with radical nephrectomy rather than routine or considered adrenalectomy [27]. However, adrenal malignancies from renal cancers are often as a result of local invasion of renal cancer cells to the ipsilateral adrenal gland rather than traditional metastasis of the renal cancer [28].

Concluding statements

In this study, we explored the technological advancements in imaging, biopsy, and biochemical evaluation and their roles in detecting adrenal metastasis. Although the detection of adrenal metastasis remains infrequent without a primary cancer diagnosis or autopsy, the development of screening technologies has improved the accuracy in identifying these lesions. Therefore, when screenings are conducted, adrenal metastases are more likely to be properly diagnosed, which allows for a better prognosis as early detection is key to treatment.

Acknowledgements

None.

Ethical policy

All procedures performed in this study were in accordance with the ethical standards of the institutional and/or national research committee and with the 1964 Helsinki declaration and its later amendments or comparable ethical standards. Informed consent was obtained from all individual participants included in the study. Approval from institutional ethical committee was taken.

Availability of data and materials

All data generated or analysed during this study are included in this publication.

Author contributions

Mark R. Wakefield initiated the idea and supervised the whole process. Sarah E. Matusofsky and Paris M. Fang wrote the draft. Ellie R. Monnette drafted Figure 1. Austin M. Kim, Mark R. Wakefield made the critical revision to the draft.

Competing interests

The authors report no conflict of interest.

Funding

None.

References

1. Cingam SR, Mukkamalla SKR, Karanchi H: Adrenal Metastasis. In: StatPearls [Internet]. Treasure Island: StatPearls Publishing 2023 Jan.
2. Vincent JM, Morrison ID, Armstrong P, Reznick RH: The size of normal adrenal glands on computed tomography. *Clin Radiol* 1994, 49(7): 453-455.
3. Shiue K, Song A, Teh BS, Ellis RJ, Yao M, Mayr NA, Huang Z, Sohn J, Machtay M, Lo SS: Stereotactic body radiation therapy for metastasis to the adrenal glands. *Expert Rev Anticancer Ther* 2012, 12(12): 1613-1620.
4. Shaheen O, Ghibour A, Alsaïd B: Esophageal Cancer Metastases to Unexpected Sites: A Systematic Review. *Gastroenterol Res Pract* 2017, 2017: 1657310.
5. Kawai N, Tozawa K, Yasui T, Moritoki Y, Sasaki H, Yano M, Fujii Y, Kohri K: Laparoscopic adrenalectomy for solitary adrenal metastasis from lung cancer. *JSLRS* 2014, 18(3): e2014.00062.
6. Almeida MQ, Bezerra-Neto JE, Mendonça BB, Latronico AC, Fragoço MCBV: Primary malignant tumors of the adrenal glands. *Clinics* 2018, 73(suppl 1): e756s.
7. Klikovits T, Lohinai Z, Fábrián K, Gyulai M, Szilasi M, Varga J, Baranya E, Pipek O, Csabai I, Szállási Z: New insights into the impact of primary lung adenocarcinoma location on metastatic sites and sequence: A multicenter cohort study. *Lung Cancer* 2018, 126: 139-148.
8. Blažeković I, Jukić T, Granić R, Punda M, Franceschi M: An Unusual Case of Papillary Thyroid Carcinoma Iodine-131 Avid Metastasis to the Adrenal Gland. *Acta Clinica Croatica* 2018, 57(2): 372-376.
9. Teegen EM, Mogl MT, Pratschke J, Rayes N: Adrenal Metastasis of Hepatocellular Carcinoma in Patients following Liver Resection or Liver Transplantation: Experience from a Tertiary Referral Center. *Int J Surg Oncol* 2018, 2018: 4195076.
10. Haider AA, Ruiz de Villa A, Frimer L, Bazikian Y: Metastasis of Melanoma to the Adrenal Glands: A Case Report and Literature Review. *Cureus* 2022, 14(7): e26749.
11. Crimi F, Quaia E, Cabrelle G, Zanon C, Pepe A, Regazzo D, Tizianel I, Scaroni C, Ceccato F: Diagnostic Accuracy of CT Texture Analysis in Adrenal Masses: A Systematic Review. *Int J Mol Sci* 2022, 23(2): 637.
12. Elsayes KM, Emad-Eldin S, Morani AC, Jensen CT: Practical Approach to Adrenal Imaging. *Urol Clin North Am* 2018, 45(3): 365-387.
13. Mao JJ, Dages KN, Suresh M, Bancos I: Presentation, Disease

- Progression, and Outcomes of Adrenal Gland Metastases. *Clin Endocrinol (Oxf)* 2020, 93(5): 546-554.
14. Da Dalt G, Friziero A, Grego A, Serafini S, Fassina A, Blandamura S, Sperti C: Adrenal metastasis from endometrial cancer: A case report. *World J Clin Cases* 2019, 7(14): 1844-1849.
 15. He X, Soleimanpour SA, Clines GA: Adrenal metastasis as the initial diagnosis of synchronous papillary and follicular thyroid cancer. *Clin Diabetes Endocrinol* 2020, 6(1): 19.
 16. Washino S, Hirai M, Matsuzaki A, Kobayashi Y: Long-term survival after adrenalectomy for asynchronous metastasis of bladder cancer to the bilateral adrenal glands. *Case Rep Urol* 2012, 2012: 425230.
 17. Patel S, Jinjuvadia R, Devara A, Naylor PH, Anees M, Jinjuvadia K, Al-Haddad M: Performance characteristics of EUS-FNA biopsy for adrenal lesions: A meta-analysis. *Endoscopic Ultrasound* 2019, 8(3): 180-187.
 18. Sharma KV, Venkatesan AM, Swerdlow D, DaSilva D, Beck A, Jain N, Wood BJ: Image-guided adrenal and renal biopsy. *Tech Vasc Interv Radiol* 2010, 13(2): 100-109.
 19. Teegeen EM, Mogl MT, Pratschke J, Rayes N: Adrenal Metastasis of Hepatocellular Carcinoma in Patients following Liver Resection or Liver Transplantation: Experience from a Tertiary Referral Center. *Int J Surg Oncol* 2018, 2018: 4195076.
 20. Alshahrani MA, Bin Saeedan M, Alkhunaizan T, Aljohani IM, Azzumeeha FM: Bilateral adrenal abnormalities: imaging review of different entities. *Abdom Radiol (NY)* 2018, 44: 154-179.
 21. Hood MN, Ho VB, Smirniotopoulos JG, Szumowski J: Chemical shift: the artifact and clinical tool revisited. *Radiographics* 1999, 19(2): 357-371.
 22. d'Amuri FV, Maestroni U, Pagnini F, Russo U, Melani E, Ziglioli F, Negrini G, Cella S, Cappabianca S, Reginelli A: Magnetic resonance imaging of adrenal gland: state of the art. *Gland Surg* 2019, 8(Suppl 3): S223-S232.
 23. Beiderwellen K, Geraldo L, Ruhlmann V, Heusch P, Gomez B, Nensa F, Umutlu L, Lauenstein TC: Accuracy of [18F] FDG PET/MRI for the Detection of Liver Metastases. *PLoS One* 2015, 10(9): e0137285.
 24. Farrugia FA, Martikos G, Tzanetis P, Charalampopoulos A, Misiakos E, Zavras N, Sotiropoulos D: Pheochromocytoma, diagnosis and treatment: Review of the literature. *Endocr Regul* 2017, 51(3): 168-181.
 25. Martinez M, LeBlanc J, Al-Haddad M, Sherman S, DeWitt J: Role of endoscopic ultrasound fine-needle aspiration evaluating adrenal gland enlargement or mass. *World J Nephrol* 2014, 3(3): 92-100.
 26. Mansour KA, Maffei V, Miller JI, Hatcher CR: Transdiaphragmatic adrenal biopsy. *Ann Thorac Surg* 1984, 38(1): 66-67.
 27. O'Malley RL, Godoy G, Kanofsky JA, Taneja SS: The necessity of adrenalectomy at the time of radical nephrectomy: A systematic review. *J Urol* 2009, 181(5): 2009-2017.
 28. Repp ML, Alvarez RA, Arevalo-Salzar DE, Kotagiri R: Metastatic renal cell carcinoma and unforeseen adrenal insufficiency: A case report and literature review. *Cureus* 2023, 15(2): e35265.