



Exploring Scrotal Leiomyomas, Unraveling the Mysteries of a Rare Tumor: A Case Report

Sana Ahuja¹, Pooja Verma¹, Adil Aziz Khan¹, Sufian Zaheer¹

Cite this article: Ahuja S, Verma P, Khan AA, Zaheer S: Exploring Scrotal Leiomyomas, Unraveling the Mysteries of a Rare Tumor: A case report. *Ann Urol Oncol* 2024, 7(1): 43-47. <https://doi.org/10.32948/auo.2024.01.28>

Abstract

Leiomyomas, originating from smooth muscle cells, are common in the uterus but rare in the scrotum, presenting a clinical challenge. Scrotal leiomyomas, first described in the 19th century, are characterized by benign pathology from the subcutaneous dartos muscle. We present two cases of middle-aged males with scrotal leiomyomas, detailing clinical presentations, histopathological findings, and immunohistochemistry results. The first involved a 48-year-old with a painless scrotal lump, excised to reveal well-circumscribed smooth muscle bundles. Immunohistochemistry confirmed vimentin, desmin, and smooth muscle actin (SMA) positivity, consistent with scrotal leiomyoma. The second case featured a 25-year-old with a painless scrotal swelling, histologically matching the features of scrotal leiomyoma. Accurate diagnosis is crucial for guiding appropriate management strategies. Clinicians often employ a combination of clinical evaluation, imaging studies, and histopathological examination to confirm the presence of scrotal leiomyomas. Ultrasound remains a valuable tool for assessing the size, location, and vascularity of the tumor, aiding in the formulation of a differential diagnosis. Definitive diagnosis, however, relies on histological examination, which typically reveals spindle-shaped smooth muscle cells arranged in interlacing bundles.

Key words scrotal, leiomyoma, sebaceous cyst, mesenchymal

1. Department of Pathology, Vardhman Mahavir Medical College and Safdarjung Hospital, New Delhi, India.

Correspondence: Sufian Zaheer (Department of Pathology, Vardhman Mahavir Medical College and Safdarjung Hospital, Ansari Nagar, New Delhi, India; Email: sufianzaheer@gmail.com).

Introduction

Leiomyomas are benign mesenchymal tumors originating from smooth muscle cells, with the majority found in the uterus, representing the most common genital tract tumor in women of reproductive age. However, these tumors can manifest in various locations throughout the body, such as the pelvis, bladder, and spermatic cord, presenting a unique challenge in clinical settings [1, 2]. One such uncommon occurrence involves the development of leiomyomas in the scrotum, a rare entity characterized by benign pathology arising from the subcutaneous dartos muscle.

Historically, scrotal leiomyomas were first described by Foster in 1858, with subsequent reports by Stout in 1937 and Seigal and Gaffey in 1964, who documented cases between 1905 and 1975 from Mayo Clinic records [3].

Leiomyoma in the scrotum is a rare phenomenon, characterized as a benign pathology arising from the subcutaneous dartos muscle [1]. Scrotal smooth muscle tumors are classified as conventional or typical leiomyomas and atypical or symplastic leiomyomas. Atypical leiomyomas exhibit abnormal nuclei that may resemble malignancy and leiomyosarcoma [4].

While leiomyomas are typically painless, they can be associated with pain and the development of hydroceles [5].

Understanding the characteristics and clinical implications of leiomyoma in the scrotum is crucial for accurate diagnosis and effective management, given its infrequent occurrence and potential overlap with more concerning pathologies.

We present two cases of scrotal leiomyomas in a 25-year-old and 48-year-old male patient respectively.

Case report

Case 1

A 48-year-old male presented with a painless lump on the right side of the scrotum persisting for the past 9 months. Upon physical examination, a firm, non-tender, mobile, and round lump

measuring 1.5 cm × 1.5 cm × 1 cm was identified at the root of the right scrotum, distinct from the testes. The overlying skin appeared normal, and no palpable inguinal lymph nodes were observed. Clinically, the lump was preliminarily diagnosed as a papilloma. Subsequently, it was excised and submitted for histopathological evaluation.

The gross examination revealed a single, partially skin-covered, grey-brown soft tissue piece measuring 1.5 cm × 1.5 cm × 0.8 cm. The cut surface exhibited a solid, and homogeneous tumor with whorling.

Microscopic examination unveiled a stratified squamous epithelial-lined tissue. In the subepithelium, a well-circumscribed tumor comprised interlacing bundles of smooth muscles with varying amounts of admixed collagen, displaying hyaline degeneration. Individual muscle cells exhibited uniform size and shape, with oval to spindle nuclei and bipolar cytoplasm. No cytological atypia or increased mitotic figures was observed. Immunohistochemistry indicated positive expression for vimentin, desmin and smooth muscle actin (SMA). Ki67 proliferation index was 2-3% (Figure 1).

The final diagnosis was confirmed as scrotal leiomyoma. The post-operative period was uneventful with no complications/recurrence till date.

Case 2

A 25-year-old man presented with complaints of scrotal swelling persisting for the past year. Upon physical examination, a firm, non-tender, mobile, round lump measuring 2 cm × 1.5 cm × 1 cm was identified on the right side of the scrotum. The lump exhibited no palpable connection to the testes, epididymis, or spermatic cord. The overlying skin appeared normal without any ulceration, and both testes were normal, with no palpable inguinal lymph nodes. Clinically, the scrotal lump was diagnosed as an epidermal inclusion cyst. The swelling was excised and submitted for histopathological examination.

The gross examination of the scrotal swelling revealed a single,

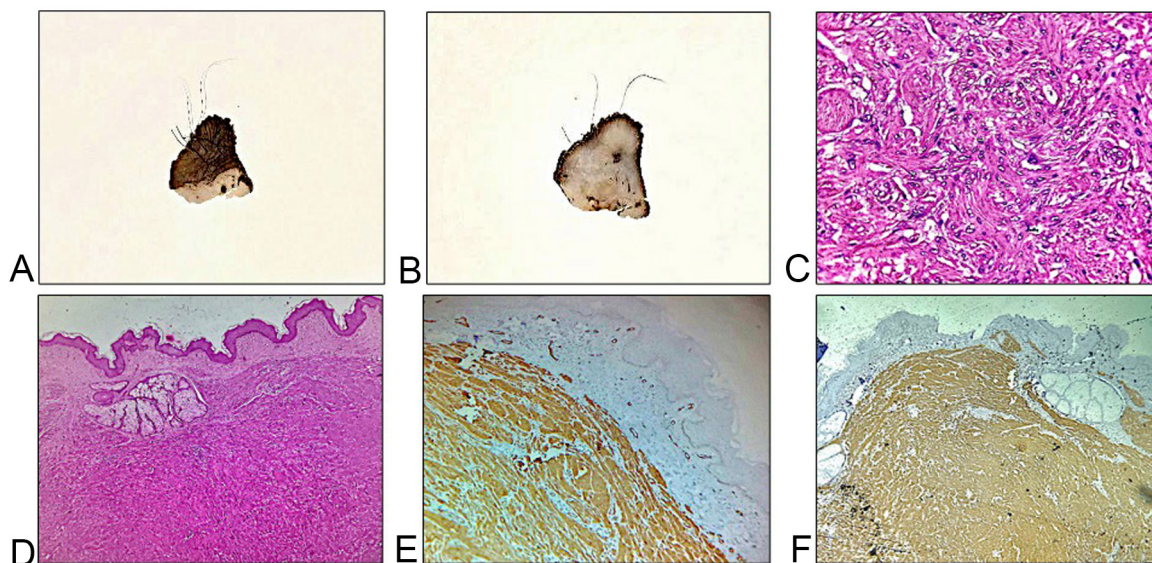


Figure 1. Gross and photomicrographs of Case 1. (A, B) Gross images show a homogeneous grey white solid tumor lying below the scrotal skin; (C, D) Hematoxylin and eosin stained sections show a well-circumscribed tumor with interlacing bundles of spindle shaped cells (40x, 400x magnification); (E, F) Immunohistochemical examination exhibited positive cytoplasmic expression for desmin and smooth muscle actin (40x magnification).

partially skin-covered, grey-brown soft tissue piece measuring 1.5 cm × 1.5 cm × 0.8 cm. The cut surface appeared solid, and homogeneous, and displayed a whorling pattern.

Microscopic examination of the scrotal swelling revealed stratified squamous epithelial-lined tissue. The subepithelium exhibited a well-circumscribed tumor composed of interlacing bundles of smooth muscles with varying amounts of admixed collagen. Individual muscle cells were uniform in size and shape, with oval to spindle nuclei and bipolar cytoplasm. No evidence of cytological atypia or mitotic figures was observed. Immunohistochemistry results indicated positivity for vimentin, desmin, and SMA (**Figure 2**). Ki67 proliferation index was 1-2%. The histopathological features were consistent with scrotal leiomyoma.

The post-operative period was uneventful with no complications/recurrence till date.

Discussion

Scrotal leiomyomas, infrequently encountered, typically manifest as asymptomatic lesions and are more commonly observed in middle-aged Caucasian men. Patients usually present with painless, small, solitary cutaneous lesions. The painless nature aligns with the tumor's slow growth, exerting pressure on nerves rather than compressing them [6-11]. While the exact etiology remains unclear, hormonal factors and genetic predispositions have been proposed as potential contributors. The rarity of scrotal leiomyomas often leads to misdiagnosis or delayed diagnosis, emphasizing the importance of raising awareness among healthcare professionals. In our cases, both patients presented with slow-growing, painless, small, solitary scrotal masses.

Scrotal smooth muscle tumors are classified into leiomyoma, atypical leiomyoma, and leiomyosarcoma. Four pathological criteria are utilized to grade scrotal smooth muscle cell tumors, including size ≥ 5 cm in greatest dimension, infiltrative margin, ≥ 5 mitotic figures per 10 high power fields, and moderate cytological atypia. Tumors meeting only one criterion are deemed benign, those fulfilling two criteria are considered atypical leiomyoma, and those demonstrating three or four criteria are classified as leiomyosarcoma.

Previously, Adil et al. (2021) reported a case of scrotal leiomyoma in an 82-year-old male with a left scrotal mass persisting for 3 years. Imaging studies revealed a left paratesticular mass, and surgery confirmed the histopathological features consistent with scrotal leiomyoma [12]. Egharevba et al. (2020) also presented a case of scrotal leiomyoma in a 39-year-old male with a progressive right-sided hemiscrotal swelling over one year, which was excised, and histopathology revealed scrotal leiomyoma [13]. **Table 1** summarizes the previously reported cases of scrotal leiomyoma.

Accurate diagnosis is crucial for guiding appropriate management strategies. Clinicians often employ a combination of clinical evaluation, imaging studies, and histopathological examination to confirm the presence of scrotal leiomyomas. Ultrasound remains a valuable tool for assessing the size, location, and vascularity of the tumor, aiding in the formulation of a differential diagnosis. Definitive diagnosis, however, relies on histological examination, which typically reveals spindle-shaped smooth muscle cells arranged in interlacing bundles.

Clinical manifestations of scrotal leiomyoma may lack distinctive characteristics, with a clinical differential diagnosis including sebaceous cysts, fibromas, adnexal tumors,

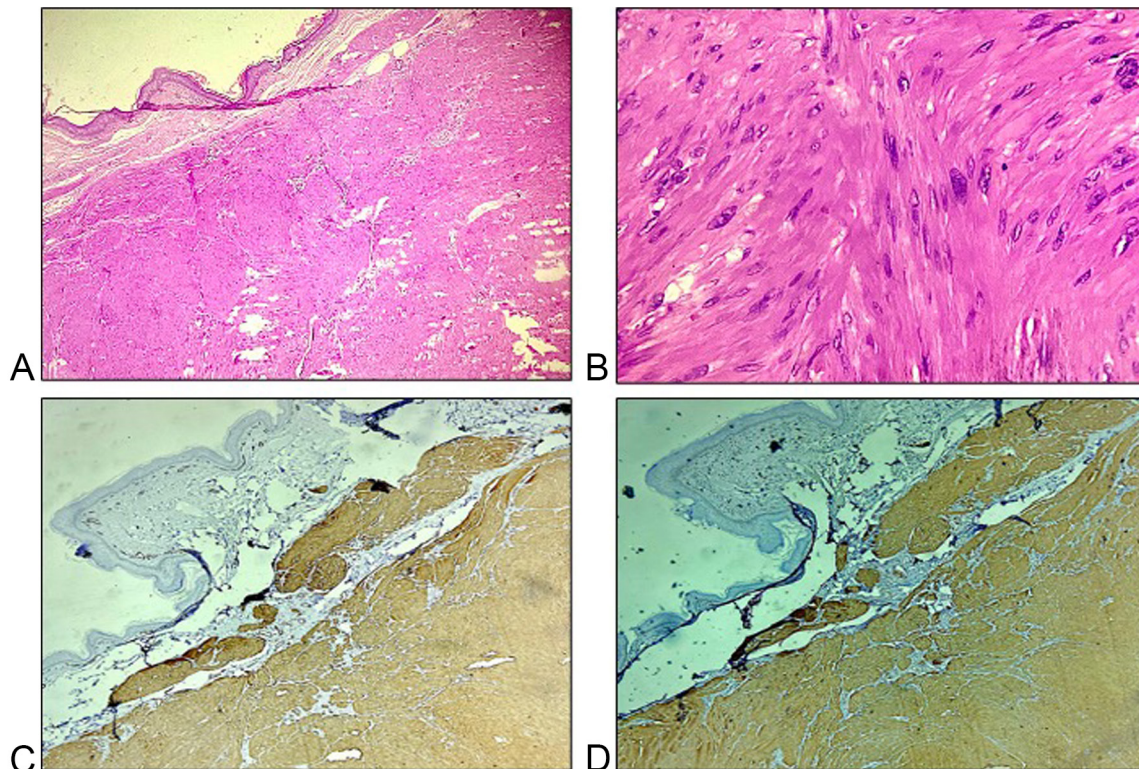


Figure 2. Histopathological and immunohistochemical images of Case 2. (A, B) Hematoxylin and eosin stained sections show a well-circumscribed tumor with interlacing bundles of spindle-shaped cells (40x, 400x magnification); (C, D) Immunohistochemical examination exhibited positive cytoplasmic expression for desmin and smooth muscle actin (40x magnification).

Table 1. Previously reported cases of scrotal leiomyoma.

Author	Age	Clinical presentation	Clinical differential	Radiological findings	Final diagnosis
Rana et al (2015) [1]	75	Painless mass right side of scrotum	Sebaceous cyst	-	Scrotal leiomyoma
Aluko et al (2018) [2]	37	Painless right scrotal mass	Lipoma/ adenomatoid tumor/ papillary cystadenoma/ leiomyoma	USG: A 5.2-cm hypoechoic vascular mass within the right scrotal sac	Scrotal leiomyoma
Ariafar et al (2020) [3]	71	Left testicular enlargement and heaviness	-	USG: Scrotal mass	Scrotal leiomyoma
Fakhraddin et al (2020) [4]	52	Painless lump, scrotum	-	USG: 40 mm × 20 mm hypoechoic, poorly vascular lesion in the scrotum	Scrotal leiomyoma
Su et al (2014) [5]	53	Painless right scrotal mass	Sebaceous cyst	-	Bizzare leiomyoma
Asotra et al (2016) [6]	50	Painless left scrotal mass	Sebaceous cyst	-	Scrotal leiomyoma
Bell et al (2016) [7]	47	Mildly painful, slowly enlarging nodule on his left hemiscrotum	Sebaceous cyst	USG: 7 mm superficial, hypoechoic soft-tissue nodule	Scrotal leiomyoma
Patel et al (2019) [8]	71	Painless left scrotal mass	-	-	Scrotal leiomyoma
Makkapati et al (2024) [9]	55	Painless right scrotal mass	Sebaceous cyst	-	Scrotal leiomyoma
Wang et al (2023) [10]	53	Constant heaviness in the right scrotum	-	USG: Well-circumscribed and heterogenous hypoechoic tumor	Scrotal leiomyoma
Sherwani et al (2008) [11]	50	Painless left scrotal mass	Sebaceous cyst	-	Scrotal leiomyoma
Adil et al (2021) [12]	82	Left scrotal enlargement	-	USG: 7 × 4cm, intra-scrotal extra-testicular well-circumscribed mass, with mixed, heterogeneous echogenicity	Scrotal leiomyoma
Egharevba et al (2020) [13]	39	Right hemiscrotal swelling	Epidermoid cyst, adenomatoid tumor	USG: 4.9 cm × 3.9 cm well-circumscribed mass with mixed echogenicity attached to the lower pole of the right testis	Scrotal leiomyoma
Li et al (2013) [14]	32	Painless right scrotal mass	-	-	Scrotal leiomyoma

neurofibromas, schwannomas (if painful), and squamous cell carcinoma (if ulcerated) [8, 14]. If there is any adhesion to the testis, consideration should be given to the possibility of atypical leiomyoma or leiomyosarcoma. Surgical excision stands as the

primary treatment for scrotal leiomyomas. Complete excision is generally curative, with a low rate of recurrence reported in the literature. Minimally invasive techniques, such as laparoscopy or sclerotherapy, have shown promising results in select cases.

However, the optimal approach may vary based on the size and location of the tumor, as well as the patient's overall health. Long-term follow-up is essential to monitor for recurrence and assess the overall prognosis [3].

Given the limited number of reported cases and the paucity of large-scale studies, scrotal leiomyomas remain an enigmatic entity in the realm of genitourinary tumors. Further research is warranted to elucidate the underlying molecular mechanisms, explore potential biomarkers for early detection, and refine treatment algorithms. Collaborative efforts among researchers and clinicians will be instrumental in creating a comprehensive understanding of scrotal leiomyomas and improving patient outcomes.

Conclusions

Scrotal leiomyomas, though rare, demand attention and careful consideration in the medical community. A deeper exploration of their clinical features, diagnostic tools, and treatment options is crucial to enhance our understanding of this unique tumor. As we continue to unravel the mysteries surrounding scrotal leiomyomas, collaborative research efforts will pave the way for improved diagnostic accuracy, optimal therapeutic interventions, and ultimately, better outcomes for affected individuals.

Acknowledgements

Not applicable.

Ethical policy

Informed patient consent was taken. Any identifying details (such as name, date of birth) of the patient will not be published.

Availability of data and materials

That data is available from the corresponding author on request.

Author contributions

All authors contributed to the study conception and design. Material preparation, data collection and analysis were performed by Pooja Verma, Sana Ahuja, Adil Aziz Khan and Sufian Zaheer. The first draft of the manuscript was written by Pooja Verma and Sana Ahuja and all authors commented on previous versions of the manuscript. All authors read and approved the final manuscript.

Competing interests

The authors have no conflicts of interest to declare.


Funding

None.

References

1. Rana S, Sharma P, Singh P, Satarkar RN: Leiomyoma of Scrotum: a Rare Case Report. *Iran J Pathol* 2015, 10: 243-247.
2. Aluko T, Masi Z, Tomaszewski J, Germaine P: Scrotal sac leiomyoma: Case report of a rare benign scrotal mass. *Radiol Case Rep* 2018, 13: 411-414.
3. Ariaifar A, Soltani M, Khajeh F, Zeighami S, Naghdi Sedeh N, Miladpour: Scrotal leiomyoma a rare benign intra-scrotal mass could lead to unnecessary orchiectomy. *Urol Case Rep* 2020, 32: 101170.
4. Fakhralddin SS, Bapir R, Babarusul MH, Ibrahim ZB, Aghaways I: Typical leiomyoma of the scrotum: A rare case report. *Int J Surg Case Rep* 2020, 67: 142-145.

5. Su Z, Li G, Wang Y, Yu Z, Chen Z, Ni L, Yang S, Ye J, Lai Y: Bizarre leiomyoma of the scrotum: A case report and review of the literature. *Oncol Lett* 2014, 7: 1701-1703.
6. Asotra S: Leiomyoma of scrotum. *Arch Med He Sci* 2016, 4: 238-240.
7. Bell RC, Austin ET, Arnold SJ, Lin FC, Walker JR, Larsen BT: Rare leiomyoma of the tunica dartos: A case report with clinical relevance for malignant transformation and HLRCC. *Case Rep Pathol* 2016, 2016: 6471520.
8. Patel H, Patel N: Leiomyoma of scrotum: A case report of a common benign tumor at a rare site. *Int J Clin Diagn Pathol* 2019, 2: 261-262.
9. Makkapati S, Venkatasubramanian R, Muralidharan M: Rare case of a scrotal leiomyoma-a diagnostic dilemma: A case report. *Int J Surg Case Rep* 2024, 114: 109178.
10. Wang P: Scrotal Leiomyoma: A Case Report of a Rare Intra-Scrotal Benign Mass. *Cur Med Imaging* 2023, 19: 962-964.
11. Sherwani RK, Rahman K, Akhtar K, Zaheer S, Hassan MJ, Haider A: Leiomyoma of scrotum. *Indian J Pathol Microbiol* 2008, 51: 72.
12. Adil H, Mrabti M, Semedo A, El Fenni J, Abdellaoui M: Scrotal leiomyoma: An uncommon cause of chronic scrotal swelling. *Radiol Case Rep* 2021, 16: 2787-2791.
13. Egharevba PA, Omoseebi O, Okunlola AI, Omisano OA: Scrotal leiomyoma: a rare cause of scrotal swelling. *Afr J Urol* 2020, 26: 1-4.
14. Li SL, Han JD: A case report of atypical scrotal leiomyoma. *Case Rep Dermatol* 2013, 5: 316-320.

 Copyright © 2024 Ann Urol Oncol. This work is licensed under a Creative Commons Attribution-NonCommercial-No Derivatives 4.0 International (CC BY-NC-ND 4.0) License.