



## Research Progress in Focal Treatment of Prostate Cancer

Songtao Cheng<sup>1</sup>, Shize Wang<sup>1</sup>, Jing Liu<sup>1</sup>, Jianlin Huang<sup>1</sup>, Jiannan Liu<sup>1</sup>

Cite this article: Cheng S, Wang S, Liu J, Huang J, Liu J: Research Progress in Focal Treatment of Prostate Cancer. *Ann Urol Oncol* 2023, 6(2): 79-86. <https://doi.org/10.32948/auo.2023.06.24>

### Abstract

Prostate cancer is the second most common malignant tumor in men worldwide, and its incidence is increasing in China. Treatment methods of prostate cancer include surgery, radiotherapy, chemotherapy, endocrine therapy, and local therapy. Compared to all treatment options for prostate cancer, local treatment has the advantage of less trauma and fewer complications. With the wide application of PSA screening, improvement and enhancement of transperineal puncture technology under template positioning and the development of multi-parameter MRI, more and more low-grade and localized prostate cancer are detected. Most prostate cancer patients receive total gland therapy after diagnosis, but patients with localized prostate cancer may not benefit from treatment because of the side effects of total gland therapy. With the development of imaging technology and the "main focus" theory, focal therapy techniques have been greatly developed. Focal therapy (FT) is a treatment method for localized prostate cancer (Pca), which mainly targets low and medium-risk localized disease to reduce whole-gland treatment. Such as radical prostatectomy (RP) or the adverse effects of radical external radiotherapy, FT has the advantage of preserving more sexual and bladder function while controlling the tumor. The current focal therapy techniques used in clinic mainly include high-intensity focused ultrasound, focal laser ablation, cryotherapy, irreversible electroporation, and photodynamic therapy. In this study, we reviewed the clinical trials of focal therapy in recent years and found that high-intensity focused ultrasound and focal laser ablation have better failure-free survival and postoperative functional control.

**Key words** prostate cancer, focal treatment, high intensity focused ultrasound, focal laser ablation, cryotherapy

1. Department of Urology, Sichuan Provincial People's Hospital, University of Electronic Science and Technology of China, Chengdu 610072, China.

Correspondence: Jiannan Liu (Department of Urology, Sichuan Provincial People's Hospital, University of Electronic Science and Technology of China, No. 32, West Section 2, First Ring Road, Chengdu, China, 610072, China; Email: liujiannan1213@163.com).

## Introduction

Prostate cancer is one of the most common malignancies in men. According to the latest global tumor data, prostate cancer is the second most common malignancy among men in 2020, after lung cancer, and its fatality rate ranks fifth globally [1]. In China, although the incidence of prostate cancer is lower than that of European and American countries, it has increased significantly in recent years within the aging population [2]. Especially with the popularization of prostate-specific antigen (PSA) screening, more and more early localized anterior adenocarcinoma are detected [3]. By analyzing data released by the World Health Organization, China will have about 110,000 new cases of prostate cancer in 2020, which ranks 10th among malignant tumors. The number of deaths in that year was about 50,000, and the total number of cases in five years will be about 400,000. Patients with low-risk localized prostate cancer often opt for surveillance or whole-gland treatment. The disadvantages of monitoring are mainly repeated biopsies, which may increase the financial burden of the patient; Secondly, regular, long-term, and strict monitoring has higher requirements for patients' compliance and psychological bearing capacity [4, 5]. Total gland therapy refers to the treatment of the entire prostate, including radical prostatectomy (RP) and radical radiotherapy (RT). At present, the related complications caused by total gland therapy can not be completely avoided, such as erectile dysfunction, urinary incontinence and lymphatic fistula after radical surgery [6-8], urinary tract obstruction, bleeding, rectourethral fistula and pelvic bone complications after radiotherapy [9, 10]. Therefore, total gland therapy not only reduces patients' quality of life, but also brings additional treatment-related complications and economic burden. Due to the above shortcomings of monitoring and total glandular therapy, focal treatment of prostate cancer has gradually gained attention of urologists. Focal therapy involves the elimination of locally identified lesions while monitoring other remaining glands (Figure 1). A 2009 study showed that prostate cancer metastases originate from the same clone, known as the primary focus. If the primary focus can be accurately identified and targeted, focal treatment can lead to better therapeutic outcomes [11, 12]. This article reviews the current status of focal therapy.

## Focal location

The overall efficacy and safety of focal therapy depends on the precise localization of the tumor before and during treatment, which mainly relies on multiparametric magnetic resonance imaging (MP-MRI) before surgery. Studies showed that MP-MRI increased diffusion weighted imaging (DWI), dynamic-contrast enhanced (DCE) and apparent diffusion coefficient (ADC) images significantly aid in the improvement of prostate MRI imaging. In addition, with the release and update of prostate Image-Reporting and data system (PI-RADS), prostate imaging has provided a clear standard for the lesion score of each sequence. After synthesizing the results of each sequence to obtain an overall score, the clinical significance of the lesions can be judged more accurately [13-15]. MP-MRI cannot only locate the lesion more accurately, but also detect the morphological changes inside the tumor to evaluate its progression and treatment response [16, 17]. Felker et al. [18] confirmed that MP-MRI is significantly superior to continuous prostate specific antigen (PSA) measurement in predicting tumor residue after laser ablation of focal lesions. Nevertheless, MP-MRI also has few limitations. First, it often underestimates the size of the lesion in prostate cancer cases with a low Gleason score [19]; Second, MP-MRI may still rule out clinically significant prostate cancer, which can lead to missed lesions on biopsy or focal treatment [20]. Therefore, accurate fusion of MP-MRI and

intraoperative ultrasound is required for focal lesion localization.

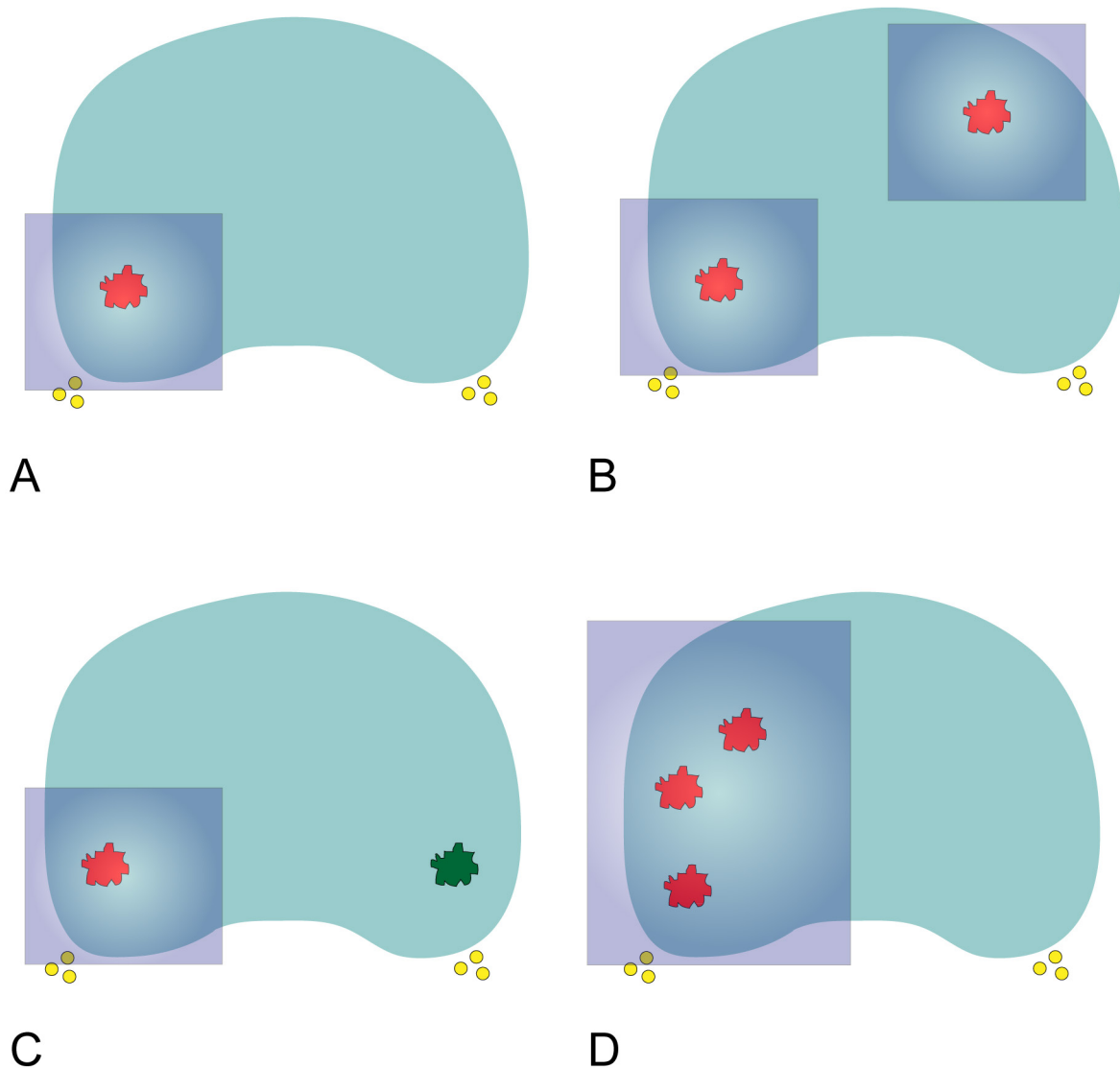
## Focal treatment

### *High intensity focused ultrasound*

High intensity focused ultrasound (HIFU) is one of the most commonly used focal treatment modalities. The ultrasound probe is placed in the rectum at the beginning of the procedure. The prostate volume is measured, and an image is created. The doctor marks the treated area on the image. Through HIFU, precise, concentrated ultrasound waves are delivered to the target tissue. Within 2-3s, the temperature of the tissue can be raised to nearly 100 °C and coagulate necrosis can occur [21]. Guillaumier et al. [22] conducted a study, which included the largest clinical trial of HIFU for prostate cancer to date, involving 625 patients with non-metastatic prostate cancer. The 5-year failure-free and overall survival rates for the entire patient cohort were 88% and 99%, respectively. Ganzer et al. [23] followed up 538 patients with local prostate cancer treated with HIFU alone in a single center for nearly 10 years. According to the statistics, the 5-year and 10-year biochemical disease-free survival rates were 81% and 61%, respectively, and the 10-year tumor-specific survival rates were as high as 94% to 97%. In another study, de Castro Abreu et al. [24] followed up 7 patients who underwent HIFU semi-glandular ablation by enhanced transrectal contrast ultrasound (TRUS). The median follow-up after HIFU was 15 (13-20) months, and the prostate volume decreased by 32.5% (range 0-74%), 82% reduction in PSA levels (range 30% to 95%). The median duration of PSA decline was 3 months (range 2 to 12 months). Nahar et al. [25] conducted a study that included a total of 52 patients, and 17% (5/30) of the patients had positive biopsy results 12 months after surgery. After 5 months, Ghai et al. [26] found that residual prostate cancer was detected in 7% (3/44) of the patients at the treatment site. In addition, Albisinni et al. [27] found no statistical difference in the probability of requiring further treatment due to disease progression after HIFU versus RP. These studies all confirmed that HIFU can achieve better tumor control outcomes in the focal treatment of prostate cancer. At the same time, HIFU also has obvious advantages in terms of safety as Guillaumier et al. [22] confirmed that 98% (241/247) of patients achieved complete pad free urine control; Nahar et al. [25] also found that the urinary system function of the patients recovered to the baseline level in 3-6 months, and the sexual function recovered in 12 months. Ghai et al. [26] proposed that the median international index of erectile function at 5 months after surgery, IIEF and international prostate symptom score (IPSS) have no significant differences with baseline prostate symptom score. HIFU has a good treatment success rate, and the safety is guaranteed. At the same time, the operation can be carried out under spinal anesthesia or intravenous anesthesia without incision on the skin, and the patients recover quickly after surgery [21]. However, in Guillaumier et al. [22] found that patient follow-up was insufficient, with only 222 patients receiving puncture biopsy after treatment, and the results obtained were not reliable enough. Therefore, clinical studies with large samples and long-term follow-up are still needed to observe the therapeutic effect of HIFU.

### *Focal laser ablation*

Focal laser ablation (FLA) is treated by inserting a small laser fiber, which is through the perineum or rectum into the tumor and using its discharge to heat up rapidly, causing coagulation necrosis in the controlled area, thereby reducing the risk of damage to adjacent structures [28]. The number of clinical studies on FLA is small, and most of them are small samples. Walser et al. [29]



**Figure 1. Diagrammatic drawing for focal therapy strategies. A: Lesion-targeted unifocal ablation; B: Lesion-targeted multifocal ablation; C: Lesion-targeted index lesion ablation; D: Region-targeted hemiablation. The red circles represents prostate cancer with clinical significance and the green circles represents prostate cancer with insignificance. The yellow circles represent the neurovascular bundles and the blue rectangle represents the ablation zone.**

conducted a study, including 120 patients with low - and medium-risk prostate cancer, 17% (20/120) of which received further treatment for recurrence after 1 year of rectal FLA treatment [29]. Alhakeem et al. [30] also reached a similar conclusion, with 20.4% (10/49) of patients still having tumors in the treated area after treatment. However, there were some evidence, which were from the United States authoritative Surveillance, Epidemiology, and End Results (SEER) database, showing that the difference in cancer specific mortality (CSM) between FLA and RP is not statistically significant [31], while RT had a significant advantage in survival benefit [32]. The advantages of FLA were mainly reflected in effectiveness and safety: most patients had no significant differences in IPSS, sexual health inventory in men (SHIM) scores. Besides that, some patients would return to baseline over time even if affected [29]. In addition, FLA can be performed under local anesthesia with less surgical risk. On the one hand, its disadvantages are reflected in the higher requirements

for clinicians in terms of technology [33], on the other hand, there is still a lack of long-term follow-up data.

#### *Cryotherapy*

Cryotherapy mainly involves quick freezing, slow thawing, and a repetition of the freeze-thaw cycle. There are two main mechanisms by which cryotherapy destroys tissue: one is cell damage from the cooling and heating cycles; The other is progressive failure of tissue microcirculation and blood vessel stasis. The temperature of frozen tissue should reach  $-50^{\circ}\text{C}$  for tumor treatment, but there is no consensus on the optimal duration of freezing [34]. Chuang et al. [35] performed negative biopsies on 61 patients who underwent half-side cryotherapy (22/27). Tan et al. [36] used fractional cryoablation, which had 1-5-year fail-free survival rates of 98%, 89%, 84%, 75%, and 75%, respectively. By risk stratification, Mercader et al. [37] found that biochemical

**Table 1. Key clinical study of different types of focal treatment for prostate cancer.**

Research	Focal ablation modality	Follow-up number	Follow-up	Results	Functional control	Reference
Guillaumier 2019	HIFU	625	NA	The 5-year failure-free and overall survival rates were 88% and 99%, respectively.	98% (241/247) of patients achieved complete pad free urine control.	[22]
Nahar 2020	HIFU	52	NA	17% (5/30) of patients had positive biopsy results at 12 months.	Urinary function recovered to baseline level in 3-6 months, and sexual function recovered in 12 months.	[25]
Ghai 2021	HIFU	44	5 months	Residual cancer at the treatment site was detected in 7% (3/44) of patients at 5 months.	There was no significant difference between the median IIEF-15 and IPSS scores and baseline data 5 months after surgery.	[26]
Albisinni 2017	HIFU vs RP	55	NA	There was no statistically significant difference in the need for remedial treatment after surgery.	NA	[27]
Walser 2019	FLA	120	1 year	After 1 year, 17% (20/120) of patients were diagnosed with tumor.	There was no significant difference in IPSS and SHIM scores before and after treatment.	[29]
Alhakeem 2019	FLA	49	NA	20.4% (10/49) of patients still had tumor in the treated area.	IPSS scores did not differ from baseline, and SHIM scores declined in the first year but did not differ from baseline at 18 months.	[30]
Zheng 2019	FLA vs RP	321 pairs	NA	FLA had a higher all-cause mortality, but no significant reduction in cancer-specific mortality.	NA	[31]
Zhou 2020	FLA vs RT	FLA (n=428) RT (n=93041)	NA	RT has obvious advantages in terms of survival benefits.	NA	[32]
Chuang 2020	Cryotherapy	61	NA	At 6 months after treatment, 82% (50/61) of the patients were positive. At 18 months after treatment, 82% (22/27) of patients had negative biopsies.	NA	[35]
Tan 2021	Cryotherapy	71	5 years	The 1-5-year failure-free survival rates were 98%, 89%, 84%, 75%, and 75%, respectively.	100% of the patients did not use urine pad, and the IIEF-5 and AUA symptom scores of the patients were decreased after decontamination.	[36]
Mercader 2020	Cryotherapy	177	5 years	The survival times of low, medium and high risk groups were 70.2%, 70.3% and 50.0%.	95% of patients maintained complete urine control.	[37]
Oishi 2019	Cryotherapy	160	5 years	The 5-year survival rate without treatment failure was 85% and the survival rate without biochemical failure was 62%.	97% of patients maintained pad free urine control, and 73% of patients could achieve full erection after surgery.	[38]
Guo 2020	Cryotherapy vs RP	Cryotherapy (n=1942) RP (n=5826)	10 years	The 10-year tumor specific survival rates of cryotherapy and surgery were 98.1% and 99.2%, respectively.	NA	[39]

HIFU: High intensity focused ultrasound; IIEF-15: International Index of Erectile Function -15; IPSS: International Prostate Symptom Score; SHIM: Male Sexual Health Questionnaire; AUA: American Urological Association; RP: Radical prostatectomy; FLA: Focal laser ablation; RT: Radical radiotherapy; IRE: irreversible electroporation; VTP: vascular targeted photodynamic therapy; NA: Not available.

**Table 1. Key clinical study of different types of focal treatment for prostate cancer (Continued).**

Research	Focal ablation modality	Follow-up number	Follow-up	Results	Functional control	Reference
Shah 2021	Cryotherapy	58	12 months	NA	The probability of returning to baseline for IPSS and IIEF scores was 78% and 85% at 12 months and 87% and 89% at 24 months.	[40]
Blazevski 2020	IRE	123	3 years	The 3-year failure-free survival rate was 96.75% and the metastasis-free survival rate was 99%.	At 24 months after treatment, 98.8% (80/81) of patients did not need to use a urine pad; 76% (40/53) maintained erectile function.	[45]
Colletini 2019	IRE	28	6 months	The recurrence rate was 17.9%.	At 12 months after surgery, there was no significant difference in urinary and reproductive function from baseline (P = 0.58 and P = 0.07).	[46]
Flegar 2021	VTP vs RP	VTP (n=41) RP (n=49)	4 years	At 12 months after VTP, 57% (12/21) of the biopsies were negative. At 24 months, 40% (2/5) were negative, and RP100% were negative.	Patients with VTP and RP retained erectile function 71% and 30%, respectively.	[51]
Gill 2018	VTP vs Active monitoring	VTP (n=201) Active monitoring (n=206)	NA	Negative rates at the most recent biopsy were 50% (104/206) in the VTP group and 14% (30/207) in the active surveillance group.	NA	[50]
Chelly 2020	VTP	82	NA	NA	Median IIEF-5 score: 3 points lower than baseline at 6 months after treatment, 1 point lower at 1 year and 2 years, no statistically significant difference from baseline at 3, 4, and 5 years.	[52]
Tarcey 2020	VTP	50	NA	82% (40/49) of patients had no detectable Gleason grade 2 or higher in their primary lesion at 3 months after treatment.	After 3 months of treatment, the median IIEF-5 score decreased by 1.0 from the baseline, the median IPSS score decreased by 1.0 from the baseline, and pad less urine control was observed in 100% of patients.	[53]

HIFU: High intensity focused ultrasound; IIEF-15: International Index of Erectile Function -15; IPSS: International Prostate Symptom Score; SHIM: Male Sexual Health Questionnaire; AUA: American Urological Association; RP: Radical prostatectomy; FLA: Focal laser ablation; RT: Radical radiotherapy; IRE: irreversible electroporation; VTP: vascular targeted photodynamic therapy; NA: Not available.

progression-free survival rates were 70.2%, 70.3% and 50% in the low, medium and high risk groups, respectively. However, their study used neoadjuvant therapy for 3 months for 5-year treatment, failure free survival rates of 85% ,meanwhile biochemical failure free survival rates of 62% in patients with larger prostate volume [38]. In addition, there was much data, which was from SEER, reflecting that the 10-year tumor-specific survival rates for cryopreservation and surgery were 98.1% and 99.2%, respectively [39]. Freezing was also associated with better outcomes. Besides that, the above studies also analyzed the safety, 95% to 100% of patients can maintain pad free urine control after surgery [36-38]. Shah et al. [40] detected that the probability of IPSS and IIEF scores returning to baseline 12 months after surgery was 78% and 85%, respectively. Through the above analysis, it can be found that cryotherapy has a good oncologic outcome, but the standardized treatment procedures still need to be further explored. Some studies suggest that 3D mapping biopsy, which is before cryotherapy for prostate cancer, can better stratify patients' risk and reduce the failure rate of treatment [41]. At the same time, cryoablation has a certain impact on function, and more exploration is needed in the subsequent use.

#### *Irreversible electroporation*

The increase in membrane permeability, that results from the application of a pulsed electric field, is known as electroporation. Electroporation can be reversible or irreversible, depending on different current parameters and cell characteristics. The principle of irreversible electroporation (IRE) stems from it [42]. IRE causes cell death by forming nanopores inside the cell membrane without causing thermal effects. There are some advantages of IRE, for example, it does not affect the therapeutic efficacy through energy dissipation due to heat loss [43]. A preclinical study in dogs showed that collagen structures such as blood vessels and nerves were not damaged after IRE treatment [44]. If this discovery is confirmed, it could encourage the wider use of IRE. Blazevski et al. [45] conducted a clinical trial including 123 patients, with a 3-year failure-free survival rate of 96.75% and a metastasis-free survival rate of 99%. Collettini et al. [46] found that the recurrence rate after 6 months was 17.9% (5/28). In addition, IRE for apex ablation of the prostate also achieved a surprising outcome, with a failure-free survival rate of 90% (36/40) after follow-up of more than 3 years [47]. Within 1 year after IRE, the overall urinary control function of patients was almost back to baseline level, and even 76% to 94% of patients maintained erectile function after surgery [45-47]. IRE has a good oncologic outcome and a low complication rate after treatment. Because it may be selective and can preserve blood vessels, nerves and other tissues, IRE has broad application prospects. The defects of IRE are mainly manifested in the need for general anesthesia and evaluation during treatment [43], and may lead to arrhythmia in patients during treatment. Nevertheless, synchronizing the pulse frequency with the heart rhythm during treatment can reduce the incidence of arrhythmias [48].

#### *Photodynamic therapy*

Photodynamic therapy (PDT) depends on three components: photosensitive compounds, visible light, and oxygen. Photosensitive compounds selectively accumulate in hyperproliferative target cells, which then undergo necrosis and apoptosis under the action of visible light and reactive oxygen species [49]. In vitro experiments, confirmed that the mechanism of photodynamic therapy, which is to change the permeability of mitochondrial membrane and eventually lead to the death of target cells, suggesting that the regulation of mitochondrial membrane permeability-related proteins may be the key to the

efficacy of photodynamic therapy [50]. This study focuses on vascular targeted photodynamic therapy (VT-P). Flegar et al. [51] made a comparison between VTP and RP, and the conclusion was not optimistic. However, the follow-up in this study was weak, and there was no matching between VTP and RP patients, at the same time only 79% of patients received MP-MRI and targeted needle biopsy before VTP, resulting in biased results. Compared with active monitoring, VTP still had a greater advantage. After 4 years, the negative rate of biopsy in the VTP group and the active monitoring group was 50% (104/206) and 14 (30/207), respectively. The probability of further treatment after VTP was also lower. There are some side effects of VTP, and Flegar et al. [51] found that 12% of the patients had obstruction of the bladder opening. Grade 3 treatment-related adverse effects occurred in 12% (6/50) of patients included in their study. Besides that, urination and erectile function scores decreased after VTP, and it took longer for patients to return to baseline [52, 53]. VTP is also a promising treatment for localized prostate cancer. However, there are few studies on VTP, and they are small sample studies, with relatively poor oncology outcomes, and more and longer follow-up is needed to determine its efficacy and side effects.

**Figure 1** shows the focal therapy strategies in clinical application. **Table 1** is a summary on key clinical study of different types of focal treatment for prostate cancer.

#### **Summary and Prospects**

The mechanisms and the highlights of various focal treatments are summarized in Table 1 and Table 2. It shows that HIFU and FLA have better failure-free survival rate and postoperative functional control, and the treatment process is more perfect and standard. Combined with the expert consensus in recent years and the experience of Gulou Hospital, the ideal patients for focal treatment of prostate cancer are: (1) PSA < 15 ng /mL; (2) Clinical stage ≤ T2a; (3) Gleason score ≤ 3+4 (ISUP2); (4) Life expectancy > 10 years; (5) PI-RADS score 4-5 points (no capsular and seminal vesicle infiltration); (6) The patient is fully informed [54, 55].

Combined with the above discussion, the following types of patients can also be considered for focal treatment: (1) newly detected prostate cancer patients unwilling to accept active monitoring; (2) Wish to maximize the preservation of original function; (3) Old age or can not tolerate general anesthesia surgery. Despite the lack of long-term follow-up data, focal therapy remains a promising treatment option for localized prostate cancer. Nevertheless, a consensus of indications, as well as a more standard treatment regimen needs to be reached by domestic and international experts before it can be widely used, meanwhile its long-term oncology outcomes and impact on patient quality of life must be thoroughly analyzed.

#### **Acknowledgements**

We thank Dr. Sanjay Gupta (Case Western Reserve University & UH Cleveland Medical Center) for his proofreading for the review.

#### **Ethical policy**

All procedures performed in this study were in accordance with the ethical standards of the institutional and/or national research committee and with the 1964 Helsinki declaration and its later amendments or comparable ethical standards. Informed consent was obtained from all individual participants included in the study. Approval from institutional ethical committee was taken.

#### **Availability of data and materials**

All data generated or analysed during this study are included in this publication.

#### Author contributions

STC and SZW wrote the manuscript draft and prepared the figures and tables. JL and JLH edited the final manuscript. JNL approved the final manuscript and came up with the topic.

#### Competing interests

All authors declare no competing interests.

#### Funding

This work was funded by Sichuan Provincial People's Hospital Project (grant number 2022QN01).

#### References

- Sung H, Ferlay J, Siegel RL, Laversanne M, Soerjomataram I, Jemal A, Bray F: Global Cancer Statistics 2020: GLOBOCAN Estimates of Incidence and Mortality Worldwide for 36 Cancers in 185 Countries. *CA Cancer J Clin* 2021, 71(3): 209-249.
- Culp MB, Soerjomataram I, Efstathiou JA, Bray F, Jemal A: Recent Global Patterns in Prostate Cancer Incidence and Mortality Rates. *Eur Urol* 2020, 77(1): 38-52.
- Chen W, Zheng R, Baade PD, Zhang S, Zeng H, Bray F, Jemal A, Yu XQ, He J: Cancer statistics in China, 2015. *CA Cancer J Clin* 2016, 66(2): 115-132.
- Bokhorst LP, Valdagni R, Rannikko A, Kakehi Y, Pickles T, Bangma CH, Roobol MJ: A Decade of Active Surveillance in the PRIAS Study: An Update and Evaluation of the Criteria Used to Recommend a Switch to Active Treatment. *Eur Urol* 2016, 70(6): 954-960.
- Tosoian JJ, Mamawala M, Epstein JI, Landis P, Macura KJ, Simopoulos DN, Carter HB, Gorin MA: Active Surveillance of Grade Group I Prostate Cancer: Long-term Outcomes from a Large Prospective Cohort. *Eur Urol* 2020, 77(6): 675-682.
- Ficarra V, Sooriakumaran P, Novara G, Schatloff O, Briganti A, Van der Poel H, Montorsi F, Patel V, Tewari A, Mottrie A: Systematic review of methods for reporting combined outcomes after radical prostatectomy and proposal of a novel system: the survival, continence, and potency (SCP) classification. *Eur Urol* 2012, 61(3): 541-548.
- Novara G, Ficarra V, Rosen RC, Artibani W, Costello A, Eastham JA, Graefen M, Guazzoni G, Shariat SF, Stolzenburg JU et al: Systematic review and meta-analysis of perioperative outcomes and complications after robot-assisted radical prostatectomy. *Eur Urol* 2012, 62(3): 431-452.
- Mottet N, van den Bergh RCN, Briers E, Van den Broeck T, Cumberbatch MG, De Santis M, Fanti S, Fossati N, Gandaglia G, Gillessen S et al: EAU-EANM-ESTRO-ESUR-SIOG Guidelines on Prostate Cancer-2020 Update. Part 1: Screening, Diagnosis, and Local Treatment with Curative Intent. *Eur Urol* 2021, 79(2): 243-262.
- Matta R, Chapple CR, Fisch M, Heidenreich A, Herschorn S, Kodama RT, Koontz BF, Murphy DG, Nguyen PL, Nam RK: Pelvic Complications After Prostate Cancer Radiation Therapy and Their Management: An International Collaborative Narrative Review. *Eur Urol* 2019, 75(3): 464-476.
- Wallis CJD, Glaser A, Hu JC, Huland H, Lawrentschuk N, Moon D, Murphy DG, Nguyen PL, Resnick MJ, Nam RK: Survival and Complications Following Surgery and Radiation for Localized Prostate Cancer: An International Collaborative Review. *Eur Urol* 2018, 73(1): 11-20.
- Ahmed HU: The index lesion and the origin of prostate cancer. *N Engl J Med* 2009, 361(17): 1704-1706.
- Liu W, Laitinen S, Khan S, Vihinen M, Kowalski J, Yu G, Chen L, Ewing CM, Eisenberger MA, Carducci MA et al: Copy number analysis indicates monoclonal origin of lethal metastatic prostate cancer. *Nat Med* 2009, 15(5): 559-565.
- Ahmed HU, El-Shater Bosaily A, Brown LC, Gabe R, Kaplan R, Parmar MK, Collaco-Moraes Y, Ward K, Hindley RG, Freeman A et al: Diagnostic accuracy of multi-parametric MRI and TRUS biopsy in prostate cancer (PROMIS): a paired validating confirmatory study. *Lancet* 2017, 389(10071): 815-822.
- Rouvière O, Puech P, Renard-Penna R, Claudon M, Roy C, Mège-Lechevallier F, Decaussin-Petrucci M, Dubreuil-Chambardel M, Magaud L, Remontet L et al: Use of prostate systematic and targeted biopsy on the basis of multiparametric MRI in biopsy-naive patients (MRI-FIRST): a prospective, multicentre, paired diagnostic study. *Lancet Oncol* 2019, 20(1): 100-109.
- Turkbey B, Rosenkrantz AB, Haider MA, Padhani AR, Villeirs G, Macura KJ, Tempany CM, Choyke PL, Cornud F, Margolis DJ et al: Prostate Imaging Reporting and Data System Version 2.1: 2019 Update of Prostate Imaging Reporting and Data System Version 2. *Eur Urol* 2019, 76(3): 340-351.
- Lee DJ, Ahmed HU, Moore CM, Emberton M, Ehdiaie B: Multiparametric magnetic resonance imaging in the management and diagnosis of prostate cancer: current applications and strategies. *Curr Urol Rep* 2014, 15(3): 390.
- Gupta RT, Kauffman CR, Polascik TJ, Taneja SS, Rosenkrantz AB: The state of prostate MRI in 2013. *Oncology (Williston Park)* 2013, 27(4): 262-270.
- Felker ER, Raman SS, Lu DSK, Tuttle M, Margolis DJ, EIKhoury FF, Sayre J, Marks LS: Utility of Multiparametric MRI for Predicting Residual Clinically Significant Prostate Cancer After Focal Laser Ablation. *AJR Am J Roentgenol* 2019, 213(6): 1253-1258.
- De Visschere PJ, Naesens L, Libbrecht L, Van Praet C, Lumen N, Fonteyne V, Pattyn E, Villeirs G: What kind of prostate cancers do we miss on multiparametric magnetic resonance imaging? *Eur Radiol* 2016, 26(4): 1098-1107.
- Fütterer JJ, Briganti A, De Visschere P, Emberton M, Giannarini G, Kirkham A, Taneja SS, Thoeny H, Villeirs G, Villers A: Can Clinically Significant Prostate Cancer Be Detected with Multiparametric Magnetic Resonance Imaging? A Systematic Review of the Literature. *Eur Urol* 2015, 68(6): 1045-1053.
- Barkin J: High intensity focused ultrasound (HIFU). *Can J Urol* 2011, 18(2): 5634-5643.
- Guillaumier S, Peters M, Arya M, Afzal N, Charman S, Dudderidge T, Hosking-Jervis F, Hindley RG, Lewi H, McCartan N et al: A Multicentre Study of 5-year Outcomes Following Focal Therapy in Treating Clinically Significant Nonmetastatic Prostate Cancer. *Eur Urol* 2018, 74(4): 422-429.
- Ganzer R, Fritsche HM, Brandtner A, Bründl J, Koch D, Wieland WF, Blana A: Fourteen-year oncological and functional outcomes of high-intensity focused ultrasound in localized prostate cancer. *BJU Int* 2013, 112(3): 322-329.
- de Castro Abreu AL, Ashrafi AN, Gill IS, Oishi M, Winter MW, Park D, Duddalwar V, Stern MC, Palmer SL, Aron M et al: Contrast-Enhanced Transrectal Ultrasound for Follow-up After Focal HIFU Ablation for Prostate Cancer. *J Ultrasound Med* 2019, 38(3): 811-819.
- Nahar B, Bhat A, Reis IM, Soodana-Prakash N, Becerra MF, Lopategui D, Venkatramani V, Patel R, Madhusoodanan V, Kryvenko ON et al: Prospective Evaluation of Focal High Intensity Focused Ultrasound for Localized Prostate Cancer. *J Urol* 2020, 204(3): 483-489.
- Ghai S, Finelli A, Corr K, Chan R, Jokhu S, Li X, McCluskey S, Konukhova A, Hlasny E, van der Kwast TH et al: MRI-guided Focused Ultrasound Ablation for Localized Intermediate-Risk Prostate Cancer: Early Results of a Phase II Trial. *Radiology* 2021, 298(3): 695-703.

27. Albisinni S, Aoun F, Bellucci S, Biau I, Limani K, Hawaux E, Peltier A, van Velthoven R: Comparing High-Intensity Focal Ultrasound Hemiablation to Robotic Radical Prostatectomy in the Management of Unilateral Prostate Cancer: A Matched-Pair Analysis. *J Endourol* 2017, 31(1): 14-19.
28. Colin P, Mordon S, Nevoux P, Marqa MF, Ouzzane A, Puech P, Bozzini G, Leroux B, Villers A, Betrouni N: Focal laser ablation of prostate cancer: definition, needs, and future. *Adv Urol* 2012, 2012: 589160.
29. Walser E, Nance A, Ynalvez L, Yong S, Aoughsten JS, Eyzaguirre EJ, Williams SB: Focal Laser Ablation of Prostate Cancer: Results in 120 Patients with Low- to Intermediate-Risk Disease. *J Vasc Interv Radiol* 2019, 30(3): 401-409.
30. Al-Hakeem Y, Raz O, Gacs Z, Maclean F, Varol C: Magnetic resonance image-guided focal laser ablation in clinically localized prostate cancer: safety and efficacy. *ANZ J Surg* 2019, 89(12): 1610-1614.
31. Zheng X, Jin K, Qiu S, Han X, Liao X, Yang L, Wei Q: Focal Laser Ablation Versus Radical Prostatectomy for Localized Prostate Cancer: Survival Outcomes From a Matched Cohort. *Clin Genitourin Cancer* 2019, 17(6): 464-469.
32. Zhou X, Jin K, Qiu S, Jin D, Liao X, Tu X, Zheng X, Li J, Yang L, Wei Q: Comparative Effectiveness of Radiotherapy versus Focal Laser Ablation in Patients with Low and Intermediate Risk Localized Prostate Cancer. *Sci Rep* 2020, 10(1): 9112.
33. Ahdoot M, Lebastchi AH, Turkbey B, Wood B, Pinto PA: Contemporary treatments in prostate cancer focal therapy. *Curr Opin Oncol* 2019, 31(3): 200-206.
34. Gage AA, Baust J: Mechanisms of tissue injury in cryosurgery. *Cryobiology* 1998, 37(3): 171-186.
35. Chuang R, Kinnaird A, Kwan L, Sisk A, Barsa D, Felker E, Delfin M, Marks L: Hemigland Cryoablation of Clinically Significant Prostate Cancer: Intermediate-Term Followup via Magnetic Resonance Imaging Guided Biopsy. *J Urol* 2020, 204(5): 941-949.
36. Tan WP, Chang A, Sze C, Polascik TJ: Oncological and Functional Outcomes of Patients Undergoing Individualized Partial Gland Cryoablation of the Prostate: A Single-Institution Experience. *J Endourol* 2021, 35(9): 1290-1299.
37. Mercader C, Musquera M, Franco A, Alcaraz A, Ribal MJ: Primary cryotherapy for localized prostate cancer treatment. *Aging Male* 2020, 23(5): 1460-1466.
38. Oishi M, Gill IS, Tafuri A, Shakir A, Cacciamani GE, Iwata T, Iwata A, Ashrafi A, Park D, Cai J et al: Hemigland Cryoablation of Localized Low, Intermediate and High Risk Prostate Cancer: Oncologic and Functional Outcomes at 5 Years. *J Urol* 2019, 202(6): 1188-1198.
39. Guo XX, Liu SJ, Wang M, Hou HM, Wang X, Zhang ZP, Liu M, Wang JY: Comparing the Oncological Outcomes of Cryoablation vs. Radical Prostatectomy in Low-Intermediate Risk Localized Prostate Cancer. *Front Oncol* 2020, 10: 1489.
40. Shah TT, Peters M, Miah S, Eldred-Evans D, Yap T, Hosking-Jervis F, Dudderidge T, Hindley RG, McCracken S, Greene D et al: Assessment of Return to Baseline Urinary and Sexual Function Following Primary Focal Cryotherapy for Nonmetastatic Prostate Cancer. *Eur Urol Focus* 2021, 7(2): 301-308.
41. Barqawi A, Pessoa RR, Al-Musawi M, MacDermott T, O'Donnell CI: The Impact of Performing a 3D Mapping Biopsy Prior to Primary Cryotherapy for the Treatment of Prostate Cancer. *Urology* 2020, 144: 171-176.
42. Kielbik A, Szlasa W, Saczko J, Kulbacka J: Electroporation-Based Treatments in Urology. *Cancers (Basel)* 2020, 12(8): 2208.
43. Valerio M, Ahmed HU, Emberton M: Focal Therapy of Prostate Cancer Using Irreversible Electroporation. *Tech Vasc Interv Radiol* 2015, 18(3): 147-152.
44. Tsivian M, Polascik TJ: Bilateral focal ablation of prostate tissue using low-energy direct current (LEDC): a preclinical canine study. *BJU Int* 2013, 112(4): 526-530.
45. Blazeovski A, Amin A, Scheltema MJ, Balakrishnan A, Haynes AM, Barreto D, Cusick T, Thompson J, Stricker PD: Focal ablation of apical prostate cancer lesions with irreversible electroporation (IRE). *World J Urol* 2021, 39(4): 1107-1114.
46. Collettini F, Enders J, Stephan C, Fischer T, Baur ADJ, Penzkofer T, Busch J, Hamm B, Gebauer B: Image-guided Irreversible Electroporation of Localized Prostate Cancer: Functional and Oncologic Outcomes. *Radiology* 2019, 292(1): 250-257.
47. O'Neill CH, Martin RCG, 2nd: Cardiac synchronization and arrhythmia during irreversible electroporation. *J Surg Oncol* 2020, 122(3): 407-411.
48. Luksiene Z: Photodynamic therapy: mechanism of action and ways to improve the efficiency of treatment. *Medicina (Kaunas)* 2003, 39(12): 1137-1150.
49. Xu DD, Leong MML, Wong FL, Lam HM, Hoeven R: Photodynamic therapy on prostate cancer cells involve mitochondria membrane proteins. *Photodiagnosis Photodyn Ther* 2020, 31: 101933.
50. Gill IS, Azzouzi AR, Emberton M, Coleman JA, Coeytaux E, Scherz A, Scardino PT: Randomized Trial of Partial Gland Ablation with Vascular Targeted Phototherapy versus Active Surveillance for Low Risk Prostate Cancer: Extended Followup and Analyses of Effectiveness. *J Urol* 2018, 200(4): 786-793.
51. Flegar L, Buerk B, Proschmann R, Propping S, Groeben C, Baunacke M, Herout R, Huber J, Thomas C, Borkowetz A: Vascular-targeted Photodynamic Therapy in Unilateral Low-risk Prostate Cancer in Germany: 2-yr Single-centre Experience in a Real-world Setting Compared with Radical Prostatectomy. *Eur Urol Focus* 2022, 8(1): 121-127.
52. Chelly S, Maulaz P, Bigot P, Azzouzi AR, Lebdaï S: Erectile function after WST11 vascular-targeted photodynamic therapy for low-risk prostate cancer treatment. *Asian J Androl* 2020, 22(5): 454-458.
53. van den Bos W, Muller BG, Ahmed H, Bangma CH, Barret E, Crouzet S, Eggenner SE, Gill IS, Joniau S, Kovacs G et al: Focal therapy in prostate cancer: international multidisciplinary consensus on trial design. *Eur Urol* 2014, 65(6): 1078-1083.
54. Donaldson IA, Alonzi R, Barratt D, Barret E, Berge V, Bott S, Bottomley D, Eggenner S, Ehdai B, Emberton M et al: Focal therapy: patients, interventions, and outcomes--a report from a consensus meeting. *Eur Urol* 2015, 67(4): 771-777.
55. Muller BG, van den Bos W, Brausi M, Fütterer JJ, Ghai S, Pinto PA, Popeneciu IV, de Reijke TM, Robertson C, de la Rosette JJ et al: Follow-up modalities in focal therapy for prostate cancer: results from a Delphi consensus project. *World J Urol* 2015, 33(10): 1503-1509.