



## Primary Renal Leiomyosarcoma: Case Report and Review of the Literature

Sunil V Jagtap<sup>1</sup>, Shubham S. Jagtap<sup>2</sup>, kaushiki Varshney<sup>3</sup>, Yogesh Jadhav<sup>4</sup>, Pranjal Shah<sup>3</sup>

Cite this article: Jagtap SV, Jagtap SS, Varshney K, Jadhav Y, Shah P: Primary Renal Leiomyosarcoma: Case Report and Review of the Literature. *Ann Urol Oncol* 2023; 6(1): 32-38. <https://doi.org/10.32948/auo.2023.01.28>

### Abstract

Renal leiomyosarcoma is an extremely rare malignant tumor. On clinical presentation and radio imaging it is challenging to make an accurate preoperative diagnosis. In our case, a 59-year-old female presented with history of left-sided flank pain, intermittent hematuria and weight loss of 6 months duration. She was known case of hypertension and diabetes mellitus of 20 years and on regular treatment. On the abdomino-pelvis sonography showed an exophytic cortical mass lesion measuring 4.0 x 3.8 cm lesion. Magnetic resonance imaging abdomen and pelvis (plain) shows a well defined non encapsulated exophytic predominantly solid mass lesion measuring 4.3 x 4 x 4.5 cm is noted in the anterior cortex of left kidney at interpolar region. There was no evidence of any regional or distant metastasis. Patient underwent left radical nephrectomy. On histopathology reported as renal leiomyosarcoma. Immunohistochemistry showed smooth muscle actin diffusely and desmin focally positive. We present this review of rare case of primary renal leiomyosarcoma for its clinical presentation, radiographic findings, and pathologic features.

**Key words** renal leiomyosarcoma, mesenchymal tumors of kidney, sarcomatoid renal carcinoma, kidney tumors

1. Professor, Department of Pathology, Krishna Institute of Medical Sciences Deemed University, Karad, India.

2. Assistant Lecturer, Department of Medicine, Krishna Institute of Medical Sciences Deemed University, Karad, India.

3. Assistant Lecturer, Department of Pathology, Krishna Institute of Medical Sciences Deemed University, Karad, India

4. Assistant Professor, Department of Surgery, Krishna Institute of Medical Sciences Deemed University, Karad, India.

Correspondence: Sunil Vitthalrao Jagtap (Department of Pathology, Krishna Institute of Medical Sciences, Deemed University, Karad 415110, Maharashtra, India; Email: [drsvjagtap@gmail.com](mailto:drsvjagtap@gmail.com)).

## Introduction

Renal Leiomyosarcoma (LMS) is an exceedingly uncommon tumor, accounting for 0.12% of renal malignancies [1]. It is challenging to make an accurate preoperative diagnosis related to its nonspecific diagnostic features on clinical and radiological findings. It is frequently diagnosed on histological examination. It may present similarly to other renal malignancies. On histologically LMS has to be differentiated from various mesenchymal tumors of kidney especially renal sarcomas. Grigon et al. suggested the following criteria should be met to make a diagnosis of primary renal sarcoma. The patient must not have or have had a sarcoma elsewhere to rule out metastasis, on gross morphological examination must be compatible with origin in the kidney rather than involvement due to retroperitoneal sarcoma, and sarcomatoid renal cell carcinoma must be excluded [2]. The generous renal tissue sampling and special techniques like immunohistochemistry, molecular study, electron microscopy, etc are some time required before the diagnosis of any primary renal sarcoma.

## Case report

A 59-year-old female presented with hematuria, left-sided flank pain, gradual enlarging abdominal mass and weight loss of 6 months. Patient was known case of hypertension of last 25 years and diabetes mellitus since last 10 years and was on regular treatment. She was operated for cholecystectomy 25 year back. On per abdomen examination noted a soft, tender, palpable mass at left flank measuring about 6 x 6 cm. The abdomen was slightly distended. Clinically it was suspected of renal mass lesion. On examination, blood pressure was 210/140 mmHg, pulse 92/min, regular. No pedal or generalized oedema was noted. Other systemic examinations showed mild pleural and pericardial effusion. The laboratory investigations showed hematuria, mild proteinuria, elevated C-reactive protein, leucocytosis and raised erythrocyte sedimentation rate. Renal biochemical profile showed raised blood urea-89mg/dl, serum creatinine-2.5mg/dl, while other parameters i.e electrolytes serum potassium-4.1 mEq/L, serum sodium-136 mEq/L were normal. The liver profile, thyroid profile and coagulation study were within normal limits at presentation.

On the abdomino-pelvis sonography, left kidney measured 7.8 x 4.0 cm with an exophytic cortical solid mass having partially

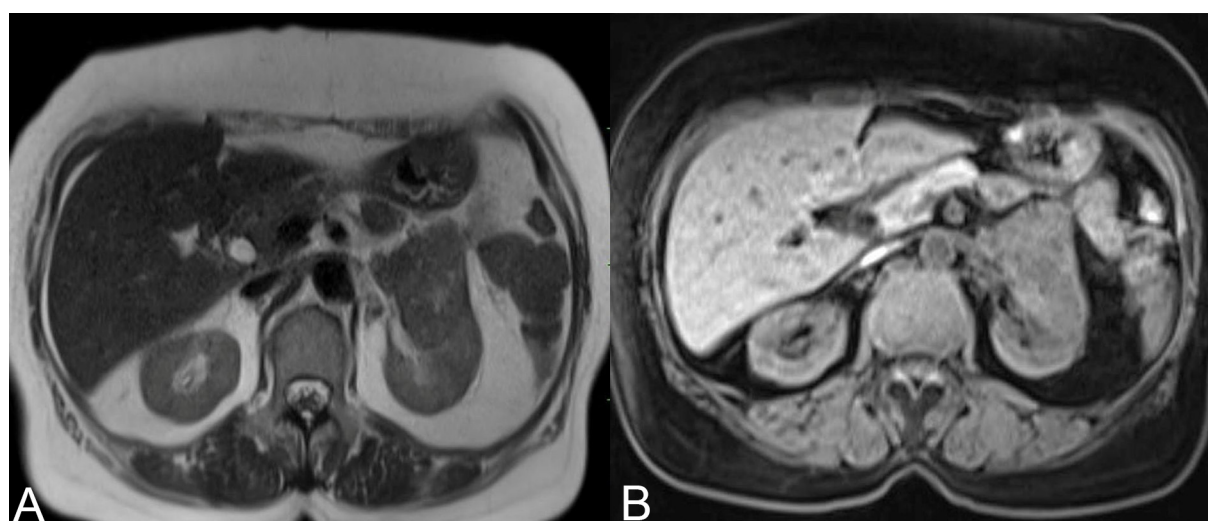
cystic areas at midpolar to hilar region. The mass measured 4.0 x 3.8 cm with septations. Right kidney measured 7.2 x 4.0 cm which was normal in size, shape and architecture. Urinary bladder was mildly dilated. Uterus showed intramural fibroid measuring 1.2 cm in maximum diameter. On sonography impression given was left renal mass suggestive of renal neoplasm with cyst and hematoma.

MRI Abdomen and pelvis (plain) showed a well defined non encapsulated exophytic predominantly solid mass lesion measuring 4.3 x 4 x 4.5 cm. It was located in the anterior cortex of left kidney at interpolar region (**Figure 1A, B**). It was isointense on T1, hypointense on T2. The lesion was seen in close proximity of left renal vein with hilar lymph node enlargement. The venous thrombosis was absent. A bone scan revealed the absence of bone metastasis. Her Right kidney was normal. Other systemic evaluations showed there was no evidence of any metastasis or any other malignancy. Other organs- urinary bladder, ovaries, liver, gall bladder, spleen, adrenals appeared normal. On MRI reported as malignant neoplastic lesion of left kidney likely to be renal cell carcinoma and advised histopathological correlation.

Patient underwent left radical nephrectomy. No adjuvant chemotherapy or radiotherapy was provided. Our patient recovered well after nephrectomy and advised follow up.

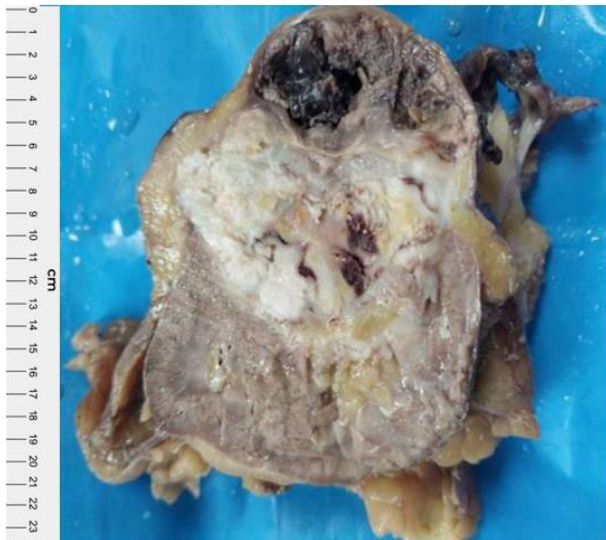We received specimen of left radical nephrectomy along with left renal hilar lymph nodes. On gross examination specimen of left radical nephrectomy totally measured 12 x 10.5 x 4.5 cm. A solid mass at mid pole of kidney extending to the renal pelvis was noted. The cut section revealed a large, well circumscribed, lobulated, greyish white firm, fleshy tumor mass with focal areas of hemorrhage and necrosis (**Figure 2**). Tumor was totally measured 5.1 x 4 x 3 cm and solid area measured 2.3 x 2 cm. Cystic area was filled with blood and largest cyst measured 2.8 x 2 cm. The three left renal hilar lymph nodes were dissected, the largest measured 2.0 x 1.0 x 0.3 cm and smallest lymph node measured 1.8 x 1 x 1 cm. The cut section of which was unremarkable.

On microscopy multiple sections were studied showed tumor composed of interlacing fascicles, whirling pattern and in sheets of neoplastic cells exhibiting spindle shaped morphology, mildly pleomorphic hyperchromatic vesicular nuclei with occasional nucleoli and eosinophilic fibrillar cytoplasm (**Figure 3, 4, 5**). Tumor showed increased mitotic figures (12/10 hpf). Tumor was infiltrating adjacent renal parenchyma. An areas of hemorrhage, necrosis was also evident. Adjacent renal parenchyma showed chronic interstitial nephritis, focal cyst formation and vascular



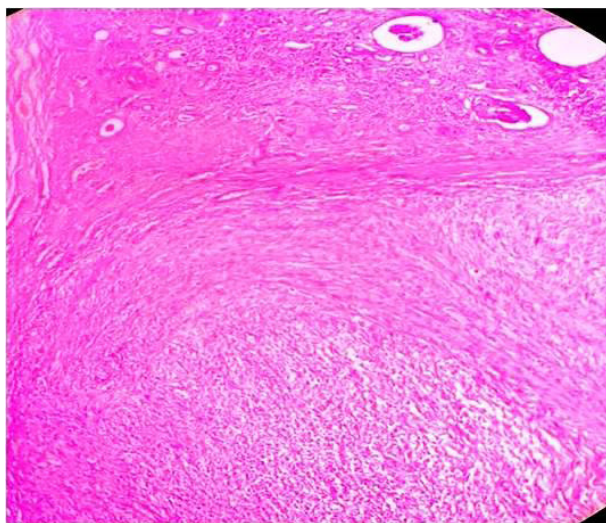
**Figure 1 A, B.** MRI Abdomen and pelvis (plain) shows a well defined non encapsulated solid mass in the anterior cortex of left kidney at interpolar region.



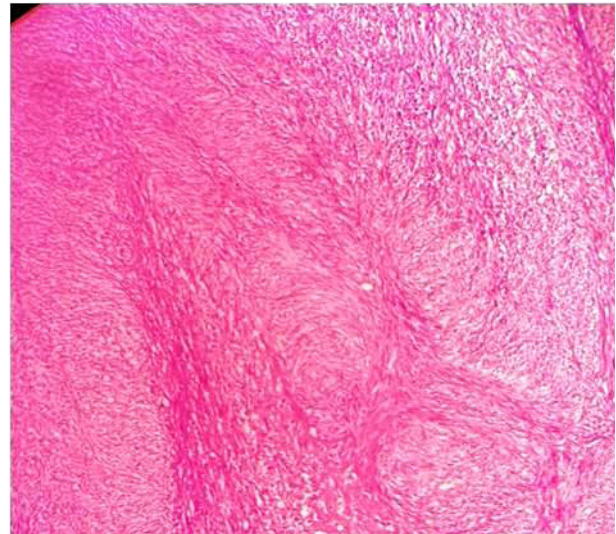


**Figure 2.** Left radical nephrectomy cut section showing a large, well circumscribed, lobulated, greyish white, firm , fleshy tumor mass with areas of necrosis and haemorrhages.

proliferation. Renal capsule, pelvis perinephric fat, renal vessels, hilar lymph nodes and ureter were free from tumor. Microscopic features were of Malignant spindle cell tumor, histomorphology diagnosed as Primary Renal Sarcoma - Leiomyosarcoma. In our case tumor differentiation was - score 1 mitotic count score 2 (12 mitoses per 10 hpf, tumor necrosis - score 2, Histologic grade-2 total score (5) as per French Federation of Cancer Centers Sarcoma Group. The special stains were done which showed, Van Gieson's and Masson's trichrome staining confirmed a smooth muscle origin. Pathological TNM staging was T2N0M0 with a negative resection margins. The immunohistochemistry for confirmation and typing was done, which showed smooth muscle actin diffusely and desmin focally positive. The patient was thoroughly investigated for any primary sarcoma elsewhere. The final diagnosis of primary renal LMS was given. On follow up patient



**Figure 3.** Photographmicrograph showing neoplastic spindle cells arranged in interlacing fascicles having pleomorphic nuclei with blunt ends and eosinophilic cytoplasm (Haematoxyline and eosin stain x40).



**Figure 4.** Tumor composed of neoplastic spindle cells having pleomorphic, hyperchromatic nuclei with occasional nucleoli and eosinophilic fibrillar cytoplasm (Haematoxyline and eosin stain x100).

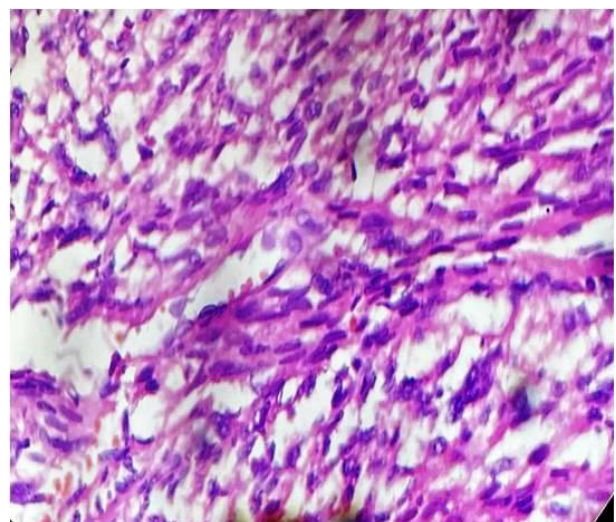
was asymptomatic and there was no evidence of any metastasis.

#### Discussion

The various malignant renal tumors of mesenchymal origin includes leiomyosarcoma, fibrosarcoma, liposarcoma, rhabdomyosarcoma, solitary fibrous tumor, malignant fibrous histiocytoma, osteosarcoma, synovial sarcoma and angiosarcoma.

Renal LMS are rare tumors of the kidney that were first reported by Berry in 1919 [3]. They comprise 0.5% to 1.5% of all malignant renal tumors in adults [4]. Prior to 1997, only 11 cases were reported in the English literature [5]. Improved diagnostic methods make current reports more frequent.

Primary sarcomas are rare in the kidney and represent 1%-2% of all malignant renal tumors with only 0.12% of renal malignancies confirmed as leiomyosarcoma [6]. On histological subtype of renal



**Figure 5.** Spindle shape tumor cells with high cellularity, pleomorphic, hyperchromatic nuclei with occasional nucleoli and eosinophilic cytoplasm (Haematoxyline and eosin stain x400).

**Table 1. Summary of primary renal leiomyosarcoma in Indians (by Dr S V Jagtap , 2023).**

S No.	Author et al / Reference	Year	Patient Age (Years)	Gender	Main Clinical symptoms	Renal Side	Radioimaging USG/CT/MRI	Gross Tumor Size (cm)	Surgery	Adjuvant Rx
1	Jagtap SV Present study	2023	59	F	hematuria, left-sided flank pain	Left	Renal Mass RCC	4.3x 4 x 4.5	Radical Nephrectomy	No
2	Karri M[24]	2022	48	F	Flank pain	Right	Renal Mass with peritoneal metastasis	7x5x4	Radical Nephrectomy	No
3	Nandi S[25]	2021	68	F	Abdominal pain	Right	Renal Mass	8x8x7	Radical Nephrectomy	No
4	Jagtap SV[8]	2021	68	M	Abdominal pain Hematuria	Right	Renal pelvis mass	3x1.9x2.4	Radical Nephrectomy	No
5	Beigh A[26]	2018	35	M	Flank Pain	Right	Renal Mass	12x5.5x4	Radical Nephrectomy	No
6			65	F	Hematuria	Left	Renal Mass	5x4x2.5	Radical Nephrectomy	No
7			55	F	Flank pain	Left	Renal Mass	7x4x2.4	Radical Nephrectomy	No
8			64	M	Flank pain	Left	Renal Mass	4x3x1	Radical Nephrectomy	No
9	Kundu R[27]	2019	65	F	Abdominal pain	Left	RCC	8x7x8	Radical Nephrectomy	No
10	Malik A[28]	2017	50	F	Flank pain	Left	RCC	8x4x2	Nephrectomy	-
11	Vasudevan S[29]	2016	57	F	Flank pain	Right	RCC	22x15x10	Radical	No
12	Rupali B[30]	2015	39	M	Abdominal lump	Left	Renal Mass	16x14x12	Partial Nephrectomy	No
13	Narula V[31]	2015	39	F	Abdominal lump	Right	Renal Mass	11x7x6	Radical Nephrectomy	No
14	Srivastav P[32]	2015	50	F	Flank pain	Left	RCC	-	-	-
15	Suresh B[33]	2014	65	F	Abdominal lump	Right	Renal Mass	18x8x7	Nephrectomy	No
16	Dhawan S[6]	2012	62	F	Abdominal pain	Left	Retroperitoneal sarcoma	10x9x8	Radical Nephrectomy	No
17	Suresh K[37]	2011	65	M	Flank pain	Right	Renal mass	-	Radical Nephrectomy	No
18	Bhat GS[34]	2011	68	M	Abdominal pain	Right	Renal mass	5.6x5.1x5	Radical Nephrectomy	No
19	Venkatesh K[35]	2010	55	F	Abdominal mass	Left	Renal mass	20x16x12	Radical Nephrectomy	No
20	Choudhury M[36]	2009	65	F	Abdominal lump	Right	Renal exophytic mass	15x11x8	Radical Nephrectomy	No
21	Dhamne S[23]	2009	60	M	Increased frequency micturition	Right	Renal hilum pelvis mass	10x8x5.6	Radical Nephrectomy	No
22	Sharma D[22]	2007	-	-	Flank pain	Left	RCC	-	Radical Nephrectomy	Adjvent chemo and radiotherapy

RCC: Renal Cell Carcinoma, USG: ultrasonography, CT: computed tomography, MRI: Magnetic resonance imaging, Adjuvant Rx: Adjuvant treatment, M: male, F: female.



sarcomas of pure mesenchymal origin, LMS is the most common variant accounting to 50-60%, followed by fibrosarcoma and liposarcoma. The renal LMS appear to arise from renal capsule or smooth muscle tissue of the vessels or renal pelvic wall [7, 8].

### Clinical Presentation

On clinical presentation the symptoms are nonspecific and often overlap with other renal pathologies. The mean age at presentation is 50-60 years with a female preponderance. The cases may present with classic triad of symptoms as an abdominal mass, flank pain, and haematuria. Rare cases presenting with spontaneous retroperitoneal hemorrhage and hypotension have been reported. The cases of renal leiomyosarcoma presents clinically and radiographically as to the common renal malignancies. On radio imaging computed tomography of renal sarcomas usually reveals a solid infiltrating mass as other common renal malignancies [9].

### Radio imaging evaluation

Advances in the imaging techniques have created great improvements in the diagnosis of renal cell carcinoma, however, renal is rare and does LMS not have known specific imaging characteristics. The computed tomography(CT) demonstrate imaging features usually reveals a solid infiltrating mass which is often very difficult to indistinguishable from renal sarcomas [10]. Due to this limitation, CT image-guided percutaneous renal mass biopsy is strongly recommended for histopathological diagnosis of the tumor with a high degree of diagnostic accuracy.

On CT renal sarcomas appearance is variable from solid masses, low attenuating to cystic. The renal LMS appear as expansile, heterogeneously-enhancing, and well-circumscribed solid masses that usually project exophytically from the kidney [11]. Large renal LMS may present as multilocular cystic masses with peripheral enhancement [9, 12].

### Pathological findings

Usually renal LMS are larger in size when detected. Miller et al. observed the mean tumor size was 13.4cm having a range from 4 to 26 cm [13]. The 60% of tumors are located on the right kidney.

On gross morphology, the tumor is well-circumscribed. On cut surface tumor show fleshy, grey white, whorled appearance with areas of haemorrhage necrosis and cystic degeneration.

The diagnosis is usually post-operative and requires a thorough sampling of the tumor. The careful evaluation for the site of tumor origin, histopathological type, its subtypes and to rule out an epithelial component especially to sarcomatoid renal cell carcinoma should be done. The common malignant renal neoplasms of pure mesenchymal origin are LMS, fibrosarcoma and liposarcoma.

On microscopically, LMS show characteristics of smooth muscle tumor. The neoplastic cells are arranged in sheaths and fascicles of spindle shaped cells having blunt ended nuclei and mild to moderate amount of eosinophilic cytoplasm. The features of malignancy are tumor necrosis, nuclear pleomorphic nuclei, and increased mitotic figures (more than 1 mitoses/10 HPF).

### Histopathological diagnosis and Differential diagnosis

According to the classification by the French Federation of Cancer Centers Sarcoma Group (FNCLCC) the pathological diagnosis and grade of the tumor was evaluated. The grade was scored based in the level of differentiation, presence of mitosis, and necrosis in each high power field [14]. The most of the renal LMS had significantly higher mitotic activity at the time of diagnosis(mean

8.6 mitoses/10 hpf), with most being FNCLCC grade 2 [15].

On histopathology the LMS has to be differentiated from sarcomatoid renal cell carcinoma, leiomyoma and renal angiomyolipoma [16, 17]. Retroperitoneal LMS, involving the kidney should be ruled out before making the diagnosis of primary renal LMS.

The low-grade LMS requires to be distinguished from a leiomyoma. In leiomyoma shows the fascicular arrangement of benign smooth muscles with no atypia the tumor cells lack of cytologic atypia and there is no necrosis. The mitotic activity is low i.e 0-1 mitoses/10 hpf.

In sarcomatoid variant of renal cell carcinoma shows a mixture of both epithelial and sarcomatoid components. The sarcomatous tumor cells are highly pleomorphic, with high mitotic activity. In tumor carefully look for any foci of classic renal cell carcinoma. Also the tumor morphologically lacks the alternating fascicles. Immunohistochemical positivity for Keratin and EMA expression. The epithelioid angiomyolipoma, a variant of angiomyolipoma, histologically can be mistaken for a LMS. The histological finding of mature adipose tissue with thick hyalinized blood vessels favors angiomyolipoma.

The other differential is primary monophasic synovial sarcoma of the kidney. It shows neoplastic spindle cells with hypercellular fascicular pattern, scant intervening stroma along with focal staghorn, branching vascular pattern. Also the fibrosarcoma and malignant peripheral nerve sheath tumor remains differential diagnosis.

### Immunohistochemistry analysis

Leiomyosarcomas on immunohistochemical analysis showed that the tumor cells were diffusely positive for smooth muscle actin. Also express positivity for calponin, desmin, and H-caldesmon. Tumor are negative for cytokeratin, S-100 protein, and HMB45, CD117 and S-100.

In the sarcomatoid renal cell carcinoma, the epithelial markers CKAE1/AE3, EMA stain positive while the like smooth muscle actin, H-caldesmon, and desmin are negative [6, 18].

The Ki-67 proliferation index, and p16 and p53 tumor suppressor proteins are over-expressed in LMS, so it could be used as a prognostic marker.

### Treatment for renal LMS

The currently recommended treatment for resectable tumors is complete surgical excision of the tumor with negative margins. Radical nephrectomy is the treatment of choice for primary renal LMS [19]. The early and complete resection of the tumor improve the overall prognosis. There is no consensus on the role of neoadjuvant or adjuvant radio/chemotherapy in the management of renal LMS [20]. Demir A, et al. observed that significant proportion of aggressive LMS that tend to recur locally, radical nephrectomy is a superior option that provides better oncologic control [21]. If the surgeon anticipates a grossly incomplete resection, intraoperative radiation therapy results in excellent local control and survival, with acceptable morbidity. Sharma et al. prescribed chemotherapy with mesna, adriamycin, ifosfamide and dacarbazine regimen and sandwich radiotherapy with a dose of 44 Gy/22#/4.5 weeks to the renal bed and adjoining lymphatics [22].

Novak M et al, stated that the neoadjuvant radiotherapy is generally administered while it is not indicated postoperatively in R0 (tumor resection with negative macro and microscopic margins) adjuvant chemotherapy is recommended in cases of R2 resections (tumors with positive macro and microscopic resection margins) as well as in unresectable and metastatic disease [20].

The regular follow-up play important role in the treatment of renal LMS.

### Prognosis

Dhamne SA et al. reported that the small tumor size (<5 cm), low histologic grade, and renal-limited disease are some favorable prognostic factors for LMS [23]. Kendal et al. reported the favorable prognostic markers are size < 4 cm, low grade, absence of nodal metastasis, and radical surgical treatment having favorable survival outcomes in the largest renal LMS cohort [1]. Novak M et al. observed that the renal LMS frequently metastasizes to distant body organs via hematogenous spread and carries an overall poor prognosis with a median overall survival of 25 months [20]. The distant metastases were identified in 90% of the patient primary LMS of the kidney in Miller et al study [13].

The study by Novak M et al. observed that the distant metastasis occurred in 30% of patients, local in 4.5%, while 15% of the patients experienced combined local recurrence and distant metastasis [20].

In Indians, renal primary leiomyosarcomas are represented mostly as case reports in the literature or as components of series of renal sarcomas as we summarized of recent cases in **table 1** [24-37]. As primary renal leiomyosarcoma is an exceedingly uncommon tumor, advances in the techniques will be helpful for improvements in the diagnosis and future plans.

### Conclusion

Primary leiomyosarcoma of the kidney is a rare renal mesenchymal tumor. These tumors does not have known specific imaging characteristics, so they should be differentiated from other renal malignancies on histopathological evaluation. The rarity of cases and absence of long-term follow up requires definitive treatment protocols.

### Acknowledgements

None.

### Ethical policy

All procedures performed in this study were in accordance with the ethical standards of the institutional and/or national research committee and with the 1964 Helsinki declaration and its later amendments or comparable ethical standards. Informed consent was obtained from all individual participants included in the study. Approval from institutional ethical committee was taken.

### Availability of data and materials

All data generated or analysed during this study are included in this publication.

### Author contributions

SVJ carried out review of various articles and texts and them compiling, proof reading, editing and final drafting of manuscript. All authors contributed to the conception, case study, analysis, interpretation, drafting the work and substantively revising it.

### Competing interests

All authors declare no competing interests.

### Funding

None.

### References

1. Kendal WS: The comparative survival of renal leiomyosarcoma. *Can J Urol* 2007, 14: 3435-3442.
2. Grignon DJ, Ayala AG, Ro JY, El-Naggar A, Papadopoulos NJ: Primary sarcomas of kidney: A clinicopathologic and DNA flow cytometric study of 17 cases. *Cancer* 1990, 65: 1611-1618.
3. Berry FB: Report of three cases of combined tumors of the kidney in adults. *J Med Res* 1919, 40(3): 459-470.
4. Yoshikawa M, Hayashi Y, Sanma S, Maruyama Y, Hirao Y, Okajima E: Spontaneous rupture of renal leiomyosarcoma: report of a case. *Hinyokika Kiyo* 1986, 32(9): 1282-1287.
5. Chen JH, Lee SK: Renal leiomyosarcoma mimicking transitional cell carcinoma. *AJR Am J Roentgenol* 1997, 169(1): 312-313.
6. S.Dhawan, P. Chopra, and S. Dhawan: Primary renal leiomyosarcoma: a diagnostic challenge. *Urology Annals* 2012, 4(1): 48-50.
7. Niceta P, Lavengood RW, Jr, Fernandes M, Tozzo PJ: Leiomyosarcoma of kidney. Review of the literature. *Urology* 1974, 3: 270-277.
8. Jagtap SV, Jagtap SS, Agarwal G, Huddedar A: Leiomyosarcoma of the renal pelvis: Rare mesenchymal tumor. *J Datta Meghe Inst Med Sci Univ* 2021, 16: 746-748.
9. Katabathina VS, Vikram R, Nagar AM, Tamboli P, Menias CO, Prasad SR: Mesenchymal neoplasms of the kidney in adults: imaging spectrum with radiologic-pathologic correlation. *Radiographics* 2010, 30(6): 1525-1540.
10. Karaosmanoğlu AD, Onur MR, Shirkhoda A, Ozmen M, Hahn PF: Unusual Malignant Solid Neoplasms of the Kidney: Cross-Sectional Imaging Findings. *Korean J Radiol* 2015, 16(4): 853-859.
11. Lalwani N, Prasad SR, Vikram R, Katabathina V, Shanbhogue A, Restrepo C: Pediatric and adult primary sarcomas of the kidney: a cross-sectional imaging review. *Acta Radiol* 2011, 52: 448-457.
12. SV Jagtap: Multilocular cystic renal neoplasm-low malignant potential (MCRN-LMP) - review. *Annals of Urologic Oncology* 2020, 3(2): 97-102.
13. Miller, Jeremy S, Zhou, Ming, Brimo, Fadi, et al: Primary Leiomyosarcoma of the Kidney: A Clinicopathologic Study of 27 Cases. *The American Journal of Surgical Pathology* 2010, 34(2): 238-242.
14. Coindre JM, Terrier P, Bui NB, Bonichon F, Collin F, Le Doussal V, et al: Prognostic factors in adult patients with locally controlled soft tissue sarcoma. A study of 546 patients from the French Federation of Cancer Centers Sarcoma Group. *J Clin Oncol* 1996, 14: 869-877.
15. Deyrup AT, Montgomery E, Fisher C: Leiomyosarcoma of the kidney: a clinicopathologic study. *Am J Surg Pathol* 2004, 28(2): 178-182.
16. Jagtap SV, Nikumbh DB, Desai SR, Kshirsagar AY, Khedkar J, Chavan SH: Unusual large sporadic angiomyolipoma coexisting with huge simple renal cyst. *Online J Health Allied Scs* 2011, 10(2): 29.
17. Mai KT, Perkins DG, Collins JP: Epithelioid cell variant of renal angiomyolipoma. *Histopathology* 1996, 28: 277-280.
18. Chow LT, Chan SK, Chow WH: Fine needle aspiration cytodiagnosis of leiomyosarcoma of the renal pelvis. A case report with immunohistochemical study. *Acta Cytologica* 1994, 38(5): 759-763.
19. Kwon YS, Salmasi A, Han CS, Hon JD, Singer EA: Renal Leiomyosarcoma: Case Report and Review of the Literature. *World J Nephrol* 2015, 4(2): 213-217.
20. Novak M, Perhavec A, Maturen KE, Pavlovic Djokic S, Jereb S, Erzen D: Leiomyosarcoma of the renal vein: analysis of outcome and prognostic factors in the world case series of 67 patients. *Radiol*

- Oncol 2017, 51(1): 56-64.
21. Demir A, Yazici CM, Eren F, Türkeri L: Case report: good prognosis in leiomyosarcoma of the kidney. *Int Urol Nephrol* 2007, 39(1): 7-10.
  22. Sharma D, Pradhan ES, Aryya NC, Shukla VK: Leiomyosarcoma of kidney: a case report with long term result after radiotherapy and chemotherapy. *Int Urol Nephrol* 2007, 39: 397-400.
  23. Dhamne SA, Gadgil NM, Padmanabhan A: Leiomyosarcoma of the renal pelvis. *Indian J Pathol Microbiol* 2009, 52: 549-551.
  24. Karri MD, Konkay K, Mandava VS, Panchakarla GV, Chaganti PD: A rare case of primary renal leiomyosarcoma with peritoneal sarcomatosis - A case report. *J NTR Univ Health Sci* 2022, 11: 152-154.
  25. Nandi S, Das S, Das C, Mukhopadhyay M: Primary renal leiomyosarcoma: A rare case report. *Indian J Case Reports* 2021, 7(11): 503-505.
  26. Beigh A, Sheikh J, Sheikh B, Mujo SP, Summyia F: Primary renal leiomyosarcoma: a rare entity. *Int J Res Med Sci* 2018, 6: 1292-1296.
  27. Kundu R, Chandra M, Punia RS, Aggarwal P: Primary renal leiomyosarcoma arising from renal vein: A case report of rare entity with review of literature. *Indian J Med Paediatr Oncol* 2019, 40: S139-S141.
  28. Malik A, Kumar R, Shankar A, Chumber S, Bakhshi S, Kaushal S, Thirunavukkarasu B: Report of primary leiomyosarcoma of renal pelvis and literature review. *J Cancer Metastasis Treat* 2017, 3: 111-115.
  29. Vasudevan S, Kumar V, Krishna B: Leiomyosarcoma of Kidney: A Rare Case Report. *Kerala Medical Journal* 2016, 9(2): 73-75.
  30. R Bavikar and S Deshmukh: Primary Leiomyosarcoma of Kidney in a Young Male Treated with Partial Nephrectomy - A Case Report *Sarcoma Res Int* 2015, 2(1): 1013.
  31. Narula V, Siraj F, Bansal A: Renal leiomyosarcoma with soft tissue metastasis: An unusual presentation. *Can Urol Assoc J* 2015, 9: E139-141.
  32. Srivastava P, Prasad R, Khanna G: Primary leiomyosarcoma of kidney: A rare case report. *Muller J Med Sci Res* 2015, 6: 157-159.
  33. Babu S, Singhai A, Hussain N, Singh V: Renal Leiomyosarcoma - A Rare Entity. *JCR* 2014, 4: 29-32.
  34. GS Bhat, GG Nelivigi, M Shivalingaiah and C S: Case Report Primary Renal Leiomyosarcoma: Case Report and Literature Review. *African Journal of Urology* 2011, 17(1): 15-17.
  35. Choudhury M, Singh SK, Pujani M, Pathania OP: A case of leiomyosarcoma of kidney clinically and radiologically misdiagnosed as renal cell carcinoma. *Indian Journal of Cancer* 2009, 46(3): 241-243.
  36. Venkatesh K, Lamba Saini M, Niveditha SR, Krishnagiri C, Babu S: Primary leiomyosarcoma of the kidney. *Patholog Res Int* 2010, 2010: 652398.
  37. Suresh Kumar, Proshan Jeet, Ranjit Kumar Das, Anup Kumar Kundu, Sandeep Gupta: Primary Renal Leiomyosarcoma: A Brief Case Report. *Uro Today Int J* 2011, 4(3): art 34.